

The European Academy of Andrology (EAA) ultrasound study on healthy, fertile men: Scrotal ultrasound reference ranges and associations with clinical, seminal, and biochemical characteristics

Lotti F¹  | Frizza F¹ | Balercia G² | Barbonetti A³ | Behre HM⁴ | Calogero AE⁵  | Cremers JF⁶ | Francavilla F³ | Isidori AM⁷  | Kliesch S⁶ | La Vignera S⁵  | Lenzi A⁷ | Marcou M⁴ | Pilatz A⁸  | Poolamets O⁹ | Punab M⁹ | Peraza Godoy MF¹⁰ | Rajmil O¹⁰  | Salvio G² | Shaer O¹¹ | Weidner W⁸ | Maseroli E¹ | Cipriani S¹ | Baldi E¹ | Degl'Innocenti S¹ | Danza G¹² | Caldini AL¹³ | Terreni A¹³ | Boni L¹⁴ | Krausz C¹  | Maggi M¹²

¹Andrology, Female Endocrinology and Gender Incongruence Unit, Department of Experimental and Clinical Biomedical Sciences "Mario Serio", University of Florence, Florence, Italy

²Endocrinology Unit, Ospedali Riuniti Ancona, Polytechnic University of Marche, Ancona, Italy

³Andrology Unit, Department of Life, Health and Environmental Sciences, University of L'Aquila, L'Aquila, Italy

⁴Center for Reproductive Medicine and Andrology, Martin Luther University Halle-Wittenberg, Halle, Germany

⁵Department of Clinical and Experimental Medicine, University of Catania, Italy

⁶Department of Clinical and Surgical Andrology, Centre of Reproductive Medicine and Andrology, Münster University Hospital, Münster, Germany

⁷Department of Experimental Medicine, Sapienza University of Rome, Rome, Italy

⁸Department of Urology, Pediatric Urology and Andrology, Justus Liebig University, Giessen, Germany

⁹Andrology Unit, Tartu University Hospital, Tartu, Estonia

¹⁰Andrology Department, Fundació Puigvert, Universitat Autònoma de Barcelona, Instituto de Investigaciones Biomédicas Sant Pau (IIB-Sant Pau), Barcelona, Spain

Abstract

Background: Scrotal color Doppler ultrasound (CDUS) still suffers from lack of standardization. Hence, the European Academy of Andrology (EAA) has promoted a multicenter study to assess the CDUS characteristics of healthy fertile men (HFM) to obtain normative parameters.

Objectives: To report and discuss the scrotal organs CDUS reference ranges and characteristics in HFM and their associations with clinical, seminal, and biochemical parameters.

Methods: A cohort of 248 HFM (35.3 ± 5.9 years) was studied, evaluating, on the same day, clinical, biochemical, seminal, and scrotal CDUS following Standard Operating Procedures.

Results: The CDUS reference range and characteristics of the scrotal organs of HFM are reported here. CDUS showed a higher accuracy than physical examination in detecting scrotal abnormalities. Prader orchidometer (PO)- and US-measured testicular volume (TV) were closely related. The US-assessed TV with the ellipsoid formula showed the best correlation with the PO-TV. The mean TV of HFM was ~ 17 ml. The lowest reference limit for right and left testis was 12 and 11 ml, thresholds defining testicular hypotrophy. The highest reference limit for epididymal head, tail, and vas deferens was 12, 6, and 4.5 mm, respectively. Mean TV was associated positively with sperm concentration and total count and negatively with gonadotropins levels and pulse pressure. Subjects with testicular inhomogeneity or calcifications showed lower sperm vitality and concentration, respectively, than the rest of the sample. Sperm normal morphology and progressive motility were positively associated with epididymal

¹¹Department of Andrology, Kasr El Aini Faculty of Medicine, Cairo University, Cairo, Egypt

¹²Endocrinology Unit, Department of Experimental and Clinical Biomedical Sciences "Mario Serio", University of Florence, Florence, Italy

¹³Department of Laboratory, Careggi Hospital, Florence, Italy

¹⁴Clinical Trials Coordinating Center, Toscano Cancer Institute, University Hospital Careggi, Florence, Italy

Correspondence

Mario Maggi, Endocrinology Unit, Department of Experimental and Clinical Biomedical Sciences, University of Florence, Viale Pieraccini 6, 50139, Florence, Italy.
Email: mario.maggi@unifi.it

Funding information

Ministry of University and Scientific Research (Scientific Independence of young Researchers [SIR] project to Francesco Lotti, Grant/Award Number: RBS114LFMQ; European Academy of Andrology

head size/vascularization and vas deferens size, respectively. Increased epididymis and vas deferens sizes were associated with MAR test positivity. Decreased epididymal tail homogeneity/vascularization were positively associated with waistline, which was negatively associated with intratesticular vascularization. CDUS varicocele was detected in 37.2% of men and was not associated with seminal or hormonal parameters. Scrotal CDUS parameters were not associated with time to pregnancy, number of children, history of miscarriage.

Conclusions: The present findings will help in better understanding male infertility pathophysiology, improving its management.

KEYWORDS

healthy fertile men, scrotal ultrasound, scrotal organs reference ranges, scrotal organs normative parameters, clinical seminal hormonal and metabolic parameters

1 | INTRODUCTION

One out of ten men of reproductive age suffers from fertility problems.¹⁻³ Despite many technical advances that have improved diagnostic skills, the causes of male infertility are still obscure in half of cases.^{1,3,4} To fill this gap, in infertility clinics the imaging of the male genital tract (MGT) has been used more and more to detect MGT abnormalities.⁴ Among imaging techniques, color Doppler ultrasound (CDUS) is the easiest to perform, less expensive, and time consuming, and is essentially free of side effects. CDUS is the gold standard for scrotal investigation, assessing reproductive-, inflammatory-, and oncological-related features.^{4,5} In fact, scrotal CDUS can detect alterations in size, echotexture, and vascularization of the testis and epididymis that could eventually be associated with sperm abnormalities or inflammation (orchitis, epididymitis).^{4,5} In particular, various testicular US parameters can be combined to predict sperm and testosterone levels impairment.⁶ In addition, scrotal CDUS can detect lesions within the testis and epididymis suggesting benign or malignant findings.^{4,5,7-11} Furthermore, scrotal CDUS provides information on epididymal and deferential abnormalities or agenesis, often correlated with obstructive infertility.^{4,5} Finally, scrotal CDUS is able to detect and stage varicocele, which can exert a negative impact on sperm parameters.^{4,5,7} Hence, scrotal CDUS has a relevant impact not only on reproductive but also on general male health, detecting abnormalities with a higher accuracy than physical examination⁴ and, often, than other imaging techniques.⁵

Although CDUS is widely used to explore the MGT, there is still no consensus on the method to assess several qualitative

and quantitative CDUS parameters.⁴ In addition, in clinical practice, there are often operator-dependent differences among sonographers in assessing and interpreting CDUS parameters. Furthermore, MGT normative parameters and the cutoff for distinguishing normal and pathologic features are still lacking.⁴ Finally, the possible correlation/impact of several CDUS findings on semen parameters and male fertility is still unclear.⁴ The aforementioned critical issues exert either a scientific or a clinical practice negative impact, including low comparability and reproducibility of data among operators, and no evidence-based CDUS reports for patients, respectively. Due to the lack of MGT-CDUS standardization, the European Academy of Andrology (EAA) has promoted an international multicenter study entitled "Standardization of the MGT-CDUS parameters in healthy, fertile men" (shortened to "EAA ultrasound study"; see <http://www.andrologyacademy.net/studies>)¹² aimed at establishing a cohort of healthy, fertile men of reference to define MGT-CDUS normative parameters. In a previous study¹³ on this cohort of 248 healthy, fertile men, we described: (a) the development and methodology of the "EAA ultrasound study," (ii) the clinical, seminal, and biochemical parameters of the cohort, and (iii) the correlations of both fertility history and seminal features with the aforementioned parameters. In particular, we reported that the seminal characteristics of the population studied were consistent with those reported by the WHO¹⁴ for the 50th and 5th centile for fertile men. This finding identifies the EAA cohort as a reference population to assess MGT-CDUS normative parameters.¹³

In the present study, we report and discuss the scrotal organs reference ranges and characteristics in healthy, fertile men, and

their associations with clinical, seminal, and biochemical parameters. Transrectal CDUS reference ranges and characteristics in fertile men will be reported separately.

2 | METHODS

The “EAA ultrasound study” was designed as a multicenter, international, observational study.¹³ Eleven EAA Centers (Ancona, Italy; Barcelona, Spain; Cairo, Egypt; Catania, Italy; Florence, Italy; Giessen, Germany; Halle, Germany; L'Aquila, Italy; Muenster, Germany; Rome, Italy; Tartu, Estonia) joined the project and enrolled 248 healthy, fertile men from February 2016 to February 2019. The inclusion criteria of the “EAA ultrasound study”¹³ were as follows: 1. healthy, fertile men (see below); 2. age \geq 18 years; 3. capacity to give consent for study participation. “Fertile men” were defined as (a) partners of a pregnant woman in the second or third trimester of pregnancy or (b) men with a child less than one year old, achieved through natural conception.¹³ “Healthy men” were defined as subjects with no personal history of previous or current systemic diseases or treatments with a recognized negative effect on semen parameters.¹³ All subjects were asked to undergo a standardized protocol performed entirely in the same day, including scrotal and transrectal CDUS before and after ejaculation; personal and medical history and physical examination; blood sampling for the determination of biochemical parameters and semen analysis.¹³ The Standard Operating Procedures (SOPs) for the assessment of scrotal CDUS qualitative and quantitative parameters and the intra- and inter-operator comparability of the MGT-CDUS parameters among different operators have been defined during investigator meetings organized before starting the enrollment of healthy, fertile men, as previously reported,⁷ and are extensively described below.

2.1 | Clinical, biochemical, and seminal parameters

The methods related to the clinical, seminal, and biochemical parameters of the cohort studied have been reported and discussed in a previous study.¹³ In particular, testicular volume (TV) was clinically assessed using the Prader orchidometer (PO), and general and andrological physical examination were carefully performed according to previous reports.¹³

2.2 | Standard Operating Procedures (SOPs) for the assessment of scrotal CDUS qualitative and quantitative parameters

The scrotal CDUS parameters to be analyzed and the methods used to evaluate them were standardized and reported at <http://www.andrologyacademy.net/studies>.¹² In addition, exemplary figures reporting (a) how to measure quantitative parameters and (b)

classifications of qualitative characteristics—using Likert scales—of the scrotal organs were reported on the EAA website,¹² and Figure 1 shows the most relevant figures. Furthermore, intra- and inter-operator comparability in assessing and interpreting MGT-CDUS parameters was evaluated (see below) in order to reduce as much as possible operator-dependent differences among sonographers. Finally, standardized schedules to report parameters detected before and after ejaculation in each EAA Center were uploaded and made available at <http://www.andrologyacademy.net/studies>.¹²

2.3 | Scrotal CDUS

Scrotal CDUS has been performed systematically on all subjects in various longitudinal, transverse, and oblique scans with the patient lying in a supine position using a high-frequency linear probe (7-15 MHz).⁴ The different EAA Centers used the following ultrasonographic consoles: Ancona, Console HD7 XE (Koninklijke Philips NV, Amsterdam, Netherlands), probe L12-5 50 mm linear array; Barcelona, ACUSON S2000™ (Siemens Medical Solutions USA, Inc), probe 18L6; Cairo, Mindray DC-3 (Shenzhen, China), linear probe 7L4A; Catania, MyLab Class C (Esaote SpA), linear probe LA523; Florence, MyLab Class C (Esaote SpA), linear probe LA523; Giessen, BK Medical Pro Focus (BK Medical), linear probe LA8811; Halle, SONOLINE G60 S (Siemens Medical Solutions), linear probe 7.5L70; L'Aquila, Logiq7 (General Electric, Healthcare), probe GE 10L; Muenster, BK Medical Pro Focus Ultraview 2202 (BK Medical), linear Probe 8670; Rome, Philips IU22 unit (Philips) with a 7-15 MHz wideband linear transducer; Tartu, Flex Focus 400 (BK Ultrasound), linear probe 8811.

2.4 | Testis and scrotal sac

The localization of the testis (scrotal sac, high scrotal, or cryptorchid position) was investigated. The three maximum diameters of each testis (anterior-posterior [height] and transverse [width] diameters in transverse scan; longitudinal diameter [length] in longitudinal scan; Figure 1, panel A) were systematically measured in all subjects. In order to assess that the same pressure was exerted both in transverse and longitudinal scans, the concordance of the anterior-posterior diameter in side-by-side transverse and longitudinal scans was checked before measuring the transversal and longitudinal testicular diameters. When the testicular longitudinal diameter was longer than the linear probe transducer and one or both testis poles were not entirely visible, the longitudinal diameter was measured using a convex probe. Testicular volume was calculated according to different mathematical formulas (ellipsoid [length x height x width x 0.52], Lambert's formula [length x height x width x 0.71], Hansen's formula [length x width² x 0.52]).^{4,15}

Testicular echotexture homogeneity was classified by the EAA ultrasound consortium on a four-point Likert scale (0. homogeneity; 1. mild (grade 1) inhomogeneity [presence of small hypoechoic foci/thin hypoechoic striae]; 2. moderate (grade 2) inhomogeneity [presence of thick hypoechoic striae]; 3. severe (grade 3) inhomogeneity

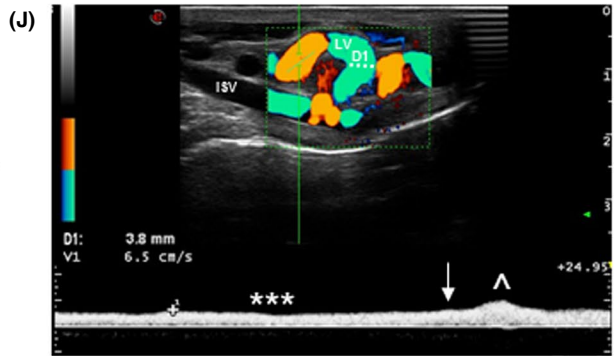
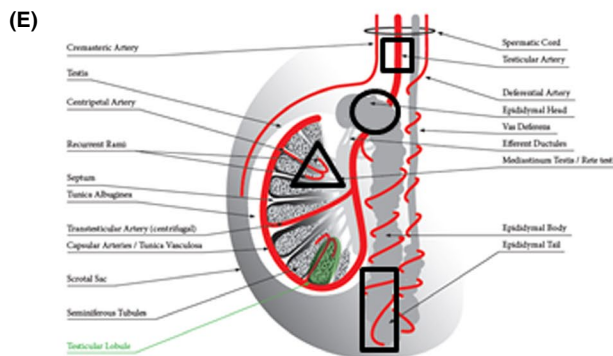
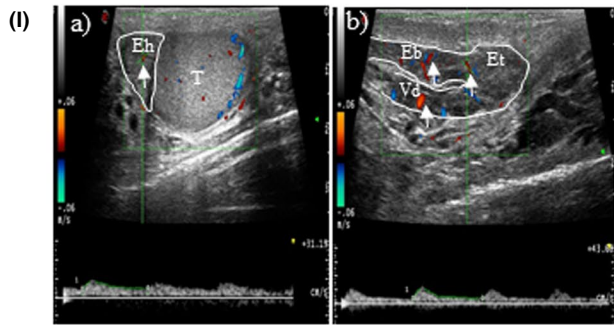
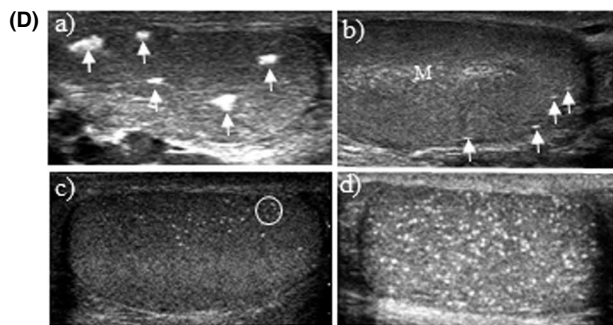
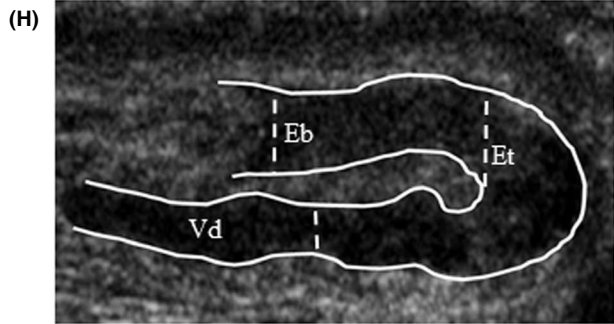
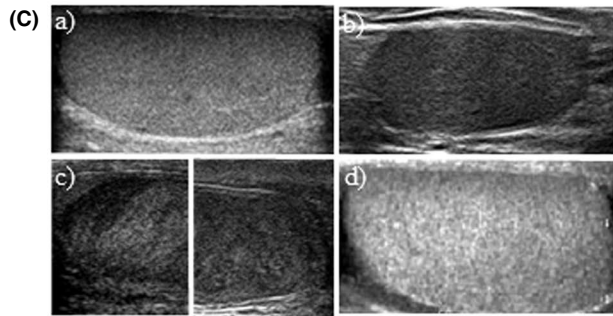
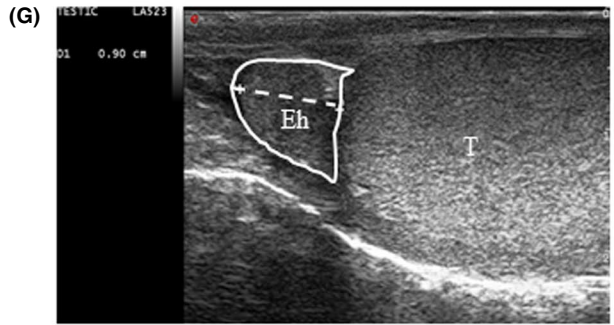
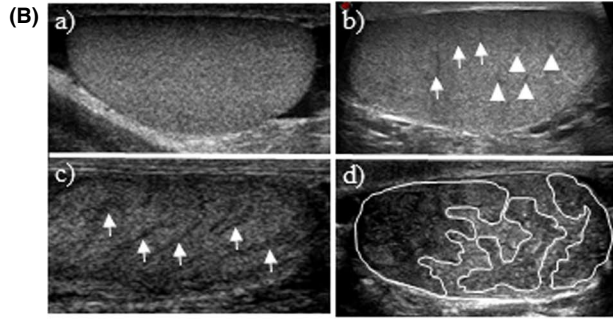
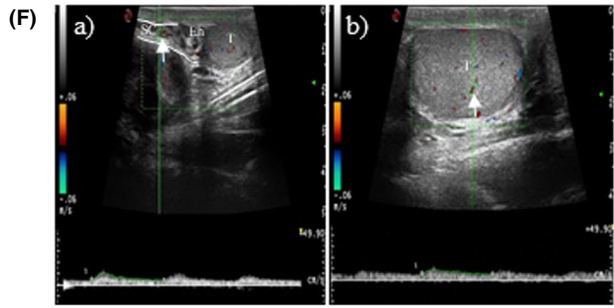
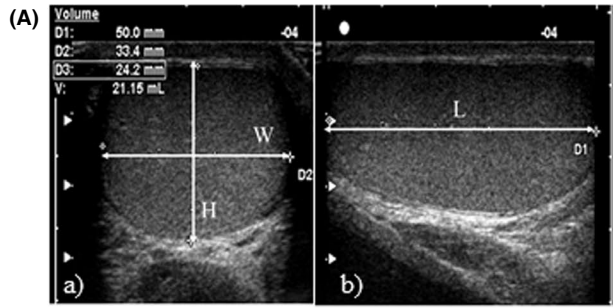


FIGURE 1 Standard Operating Procedures (SOPs) for the assessment of the main scrotal color Doppler ultrasound (CDUS) qualitative and quantitative parameters. The scrotal CDUS parameters analyzed and the methods used to evaluate them are extensively reported and discussed in the main text and at <http://www.andrologyacademy.net/studies>.¹² Panel (A) standardized measurement of the three diameters of the testis: (a) anterior-posterior diameter (D2; height [H]) and transverse diameter (D3; width [W]) in transverse scan and (b) longitudinal diameter (D1; length [L]) in longitudinal scan. V, testicular volume (reported here as automatically calculated with the ellipsoid mathematical formula). Panel (B) testicular echotexture homogeneity classification of the EAA ultrasound consortium: (a) homogeneity; (b) mild (grade 1) inhomogeneity: presence of small hypoechoic foci (arrowheads)/thin hypoechoic striae (arrows); (c) moderate (grade 2) inhomogeneity: presence of thick hypoechoic striae (arrows); (d) severe (grade 3) inhomogeneity: diffuse inhomogeneity with “netting”/“geographical map” appearance. Panel (C) testicular echogenicity classification of the EAA US consortium: (a) normoechoic; (b) and (c) mainly hypoechoic; (d) mainly hyperechoic, echotexture. Panel (D) Testicular calcifications: (a) isolated macrocalcifications (size > 3 mm); (b) isolated microcalcifications (small [1-3 mm] bright echogenic foci with no acoustic shadowing); (c) limited and “clusters” (white circle) testicular microlithiasis (presence of ≥ 5 microcalcifications in a single US scan); (d) diffuse (“starry sky” appearance) testicular microlithiasis. M, mediastinum testis. Panel (E) schematic representation of the main arterial supply to scrotal organs (adapted from reference #4) and of the areas/arteries considered by the EAA US consortium to measure testicular and epididymal arterial vascular parameters (peak systolic velocity [PSV], acceleration [A], resistive index [RI] and pulsatility index [PI]; see at <http://www.andrologyacademy.net/studies>)¹²: (a) testicular artery, sampled in the spermatic cord two centimeters before the entrance to the gonadal hilum (black square); (b) recurrent rami of the centripetal arteries (black triangle), defined in the main text as intratesticular arteries; (c) branch of the testicular artery at the epididymal head level (black circle), defined in the main text as epididymal head arterial supply; (d) deferential artery at the epididymal tail level (black rectangle), defined in the main text as epididymal tail arterial supply. Panel F, representation of sampling (a) testicular artery (arrow) and (b) intratesticular artery (recurrent branch of a centripetal artery [see above and Panel E]) (arrow) to measure testicular arterial vascular parameters (see above), showing their flow characteristics (compared with the standard ones¹⁶ to ensure that the right arteries were sampled). SC, spermatic cord; Eh, epididymal head; T, testis. Panel (G) measurement of the epididymal head (Eh, with triangular shape) length (D1; dashed line) in longitudinal scan from the top to the base of the triangle. T, testis. Panel (H) measurement of epididymal body (Eb) and tail (Et) and of vas deferens (Vd) diameters (dashed lines) in longitudinal scan. Panel I, representation of sampling (a) epididymal head arterial supply—branch of the testicular artery—(arrow) and (b) epididymal tail arterial supply—branch of the testicular artery—(arrow), to measure epididymal arterial vascular parameters (see above), showing their flow characteristics. Panel J, CDUS with spectral Doppler analysis evaluation of the pampiniform plexus, showing the internal spermatic vein (ISV)²² and the largest vein (LV).¹⁸ The diameter (D1) of the LV, measured at rest and during the Valsalva maneuver¹⁸ (arrow), is > 3 mm, indicating vein dilation. A continuous retrograde venous flow at rest (***) and its velocity (V1), as well as the venous flow increase (Δ) during Valsalva maneuver (arrow) are shown. Of note, the presence of a venous vessel dilation (> 3 mm) characterized by a continuous venous reflux at rest, increasing during Valsalva maneuver, is consistent with a grade IV varicocele according to Sarteschi et al²⁰/Liguori et al²¹ classifications,⁴ as well as with a “severe varicocele”^{4,23}

[diffuse inhomogeneity with “netting”/“geographical map” appearance]) (Figure 1, panel B). Testicular echogenicity was classified on a three-point Likert scale (0. normoechoic; 1. mainly hypoechoic; 2. mainly hyperechoic) (Figure 1, panel C).

The presence of any testicular abnormality was investigated and reported. Calcifications were assessed measuring their maximum diameter. Macrocalcifications were defined as a size > 3 mm, according to previous reports⁴ (Figure 1, panel D). Microcalcifications were defined as small (1-3 mm) bright echogenic foci with no acoustic shadowing.⁴ The maximum number of microcalcifications in a single US scan was evaluated. Testicular microlithiasis was defined as the presence of ≥ 5 microcalcifications in a single US scan⁴ and classified as limited, “clusters” or diffuse (“starry sky” appearance)⁴ (Figure 1, panel D). The localization of the calcifications was reported, considering three arbitrarily defined virtual areas of the testis: upper, middle, and lower third. Accordingly, the localization of other testicular US abnormalities (see below) was investigated considering the aforementioned virtual areas of the testis.

The presence of testicular cysts, their localization, and the three diameters of the major cyst were detected in order to calculate its volume with the ellipsoid formula. The presence of a dilated rete testis was reported, and three diameters measured in order to calculate its volume with the ellipsoid formula. The presence of testicular nodules, their three diameters, characteristics (0.cystic; 1.mixed; 2.solid), shape (0.regular; 1.irregular), homogeneity (0.homogeneous;

1.inhomogeneous), echogenicity (0.normal echogenicity; 1.mainly hypoechoic; 2.mainly hyperechoic), calcifications and/or cysts (0.absent; 1.present) and vascularization (0.absent, 1.peripheral, 2.intranodular) were assessed (see <http://www.andrologyacademy.net/studies>)¹²

Testicular arterial vascularization was also investigated. Arterial peak systolic velocity (PSV), acceleration, resistive index (RI), and pulsatility index (PI) were measured by sampling the testicular artery—in the spermatic cord, two centimeters before the entrance to the gonadal hilum¹⁵—(Figure 1, panels E and F) and by sampling the intratesticular arteries (recurrent rami of the centripetal arteries; Figure 1, panels E and F), obtaining their values as the mean of three measurements and comparing their flow characteristics with the standard ones, as previously reported,¹⁶ to ensure that the right arteries were sampled.

The presence of testis appendices was reported and the longitudinal diameter measured. The presence of extra-testicular calcifications (including scrotoliths) was reported and the major diameter measured. The presence of hydrocele was reported and three diameters measured in order to calculate its volume. A convex probe was used to assess the hydrocele when bulky.

2.5 | Epididymis and proximal vas deferens

Epididymal CDUS features were evaluated in its three segments (head, body, and tail). The longitudinal diameter of the epididymal head was

measured in a longitudinal scan from the top to the base of the triangle⁴ (Figure 1, panel G). The anterior-posterior diameters of the epididymal body and tail and of the vas deferens were measured in a single longitudinal scan according to previous studies⁴ (Figure 1, panel H).

Epididymal (three segments) and deferential homogeneity was classified as a dummy variable (0. homogeneous; 1. inhomogeneous), while echogenicity was scored on a three-point Likert scale (0. normal echogenicity; 1. mainly hypoechoic; 2. mainly hyperechoic). The presence and number of cysts of the epididymal head, body, and/or tail and of the vas deferens, and the three diameters of the major cyst for each segment was reported. The presence of calcifications as well as of appendices of the epididymal head, body, and tail or of the vas deferens were investigated and measured. Epididymal vascularization was investigated, and arterial PSV, acceleration, RI, and PI were evaluated at the level of the head (branch of the testicular artery) (Figure 1, panels E and I) and of the tail (branch of the deferential artery) (Figure 1, panels E and I). We also reported the qualitative presence of "hyperemia," defined as a "diffuse enhanced vascularization."^{4,17}

2.6 | Pampiniform plexus and varicocele

The pampiniform plexus was studied bilaterally performing grayscale and color Doppler examination with spectral Doppler analysis, with the patient supine and standing, at rest/during spontaneous breathing and during the Valsalva maneuver, according to the European Society of Urogenital Radiology (ESUR) guidelines.^{18,19} Measurement of the largest vein, irrespective of location, with the patient in the upright position (more informative than the supine one¹⁸) and during the Valsalva maneuver was performed in grayscale, according to ESUR guidelines.¹⁸ In addition, measurement of the largest vein with the patient standing, at rest, was performed according to Sarteschi et al²⁰/Liguori et al²¹ classifications (essentially overlapping⁴; see below). Furthermore, the evaluation of the maximum diameter of the internal spermatic vein between the inguinal ligament and upper pole of the testis was performed, according to a previous study,²² in order to assess a straight vein instead of the convoluted vessels below. Finally, the extension of the largest vein to the funicular region, upper or lower pole of the testis was detected. The presence of a retrograde venous flow was assessed with the patient standing, at rest, using the color Doppler with spectral Doppler analysis and angle correction, and classified as a dummy variable (0.absent or intermittent/fluctuating during spontaneous breath; 1.continuous). When a continuous retrograde venous flow at rest was detected, its velocity was measured. Therefore, the patient performed the Valsalva maneuver.

Varicocele was defined on a five-point scale, according to Sarteschi et al²⁰/Liguori et al²¹ classifications (essentially overlapping, according to reference #4), considering venous vessels > 3 mm at rest. In particular, "severe" varicocele was defined as venous vessel dilation (> 3 mm) characterized by a continuous venous reflux at rest, increasing or not during a Valsalva manoeuvre^{4,23} (Figure 1, panel J), consistent with grade IV and V varicocele according to Sarteschi

et al²⁰/Liguori et al²¹ classifications.⁴ Subclinical varicocele was defined as venous reflux detected by CDUS but not clinically evident.²⁴

2.7 | Intra- and inter-operator comparability of scrotal CDUS parameters

During the third EAA investigator meeting, held in Florence on April 20, 2013, intra- and inter-operator comparability of the MGT-CDUS parameters were assessed on seven males of infertile couples. Intra-operator comparability was assessed for the main quantitative and qualitative scrotal CDUS parameters considering the results of three evaluations for each parameter (Table 1). Inter-operator comparability was derived from the measures and observations obtained by six different sonographers (FL, FF, OP, GS, EM, SC) for the main quantitative and qualitative parameters, respectively (Table 1). The comparability of quantitative and qualitative parameters was expressed using the coefficient of variation (CV) [(standard deviation (σ) / mean (μ)) x 100] and the concordance rate (CR) [(number of concordant observations/

TABLE 1 Intra- and inter-operator comparability of the main scrotal color Doppler ultrasound parameters

	Intra-operator comparability	Inter-operator comparability
Mean TV (ml) (ellipsoid formula)	CV = 4.68	CV = 6.78
Testicular inhomogeneity (yes/no)	CR = 100%	CR = 83.3%
Testicular calcifications (yes/no)	CR = 100%	CR = 100%
Testicular artery PSV (cm/s)	CV = 4.87	CV = 8.03
Intratesticular artery* PSV (cm/s)	CV = 4.96	CV = 8.67
Epididymal head size (mm)	CV = 2.23	CV = 3.91
Epididymal tail size (mm)	CV = 4.28	CV = 4.67
Epididymal head inhomogeneity (yes/no)	CR = 100%	CR = 100%
Epididymal tail inhomogeneity (yes/no)	CR = 100%	CR = 83.3%
Vas deferens size (mm)	CV = 3.27	CV = 5.27
LV diameter (mm)	CV = 3.12	CV = 8.65
ISV diameter (mm)	CV = 2.98	CV = 8.25
LV and ISV continuous reflux presence at rest (yes/no)	CR = 100%	CR = 100%
Venous continuous reflux velocity at rest (cm/s)	CV = 4.68	CV = 7.68

Note: Data are derived from the evaluation of seven males of infertile couples. Inter-operator comparability has been obtained from measures and observations of six different sonographers. TV, testicular volume; PSV, peak systolic velocity; LV, largest vein¹⁸; ISV, internal spermatic vein²²; *intratesticular artery indicates a recurrent branch of a centripetal artery of the testis. CV = coefficient of variation [(standard deviation (σ) / mean (μ)) x 100]. A CV < 10 is considered acceptable.²⁶ CR = concordance rate, [(number of concordant observations/number of operators) X 100].

number of operators) $\times 100$], respectively.²⁵ A CV < 10 is considered acceptable.²⁶

2.8 | Statistical analysis

Data were expressed as mean \pm SD when normally distributed, as medians (quartiles) for parameters with non-normal distribution, and as percentages when categorical. The reference range for scrotal organs was estimated according to the Clinical and Laboratory Standard Institute (CLSI) Guidelines,²⁷ as the 5th and the 95th percentiles of its distribution. Correlations were assessed using Spearman's or Pearson's method, whenever appropriate. Stepwise multiple linear or logistic binary regressions were applied for multivariate analyses, whenever appropriate. When distribution could be normalized through logarithmic transformation, the same test was applied to logarithmically transformed data. For continuous parameters, a comparison between two groups in an univariate setting was performed, with unpaired two-sided Student's *t* tests for variables with normal distribution or Mann-Whitney U-test for variables with not normal distribution, and analysis of covariance (ANCOVA) was used for comparisons between two groups in a multivariate setting. Relative risk and 95% confidence interval were calculated for association of categorical parameters, and chi-squared test was used for comparisons, using the Fisher's exact test whenever appropriate. Multivariate analyses of categorical parameters were performed using a binary logistic regression model. Multivariate analyses were performed adjusting for confounders including male age, waistline, smoking habit, alcohol consumption, physical activity, calculated free testosterone levels, and number (#) of EAA Centers ("adjusted model"), unless otherwise specified. In particular, current smoking, alcohol consumption and physical activity were codified as dummy variables 0-1 (no/yes), according to a previous study.¹³ Finally, the paired two-sided Student's *t* test was used to compare scrotal CDUS parameters evaluated before and after ejaculation. All statistical analysis was performed on SPSS (Statistical Package for the Social Sciences, Chicago, IL, USA) for Windows 26.0. A $P < .05$ was considered as significant.

3 | RESULTS

Overall, 248 healthy, fertile men (35.3 ± 5.9 years; range 23-53) underwent scrotal CDUS from February 2016 to February 2019. The socio-demographic, clinical, seminal, and biochemical characteristics of the sample have been reported in a previous study.¹³

3.1 | Intra- and inter-operator comparability of scrotal CDUS parameters

Table 1 shows the intra- and inter-operator comparability of the main scrotal CDUS parameters, reporting the coefficient of variation

for quantitative parameters and the concordance rate between operators for qualitative parameters.

3.2 | Reference ranges of scrotal CDUS parameters

Table 2 shows the reference ranges of the testicular CDUS quantitative parameters, including the diameters of the testes, the testicular volume using different mathematical formulas (ellipsoid, Lambert's, Hansen's), and the main blood flow parameters of the testicular arteries (testicular artery and recurrent rami of the centripetal intratesticular arteries), as well as the prevalence of testicular echotexture abnormalities. Table 3 shows the reference ranges of the epididymal and deferential CDUS quantitative parameters, including epididymal head, body and tail, the vas deferens, and the main blood flow parameters of the epididymal arteries (branch of the testicular artery supplying the epididymal head and deferential artery supplying the epididymal tail), as well as the prevalence of epididymal echotexture abnormalities. In addition, Table 3 shows the reference ranges of the pampiniform plexus veins and the prevalence of varicocele according to the Sarteschi et al²⁰/Liguori et al²¹ classifications.⁴

Of note, no difference was observed comparing each scrotal CDUS parameter before and after ejaculation (not shown), except for testicular, intratesticular, and deferential artery PSV, which were lower before (9.0 ± 3.0 cm/s, 5.7 ± 1.1 cm/s, and 5.5 ± 1.6 cm/s, respectively) than after ejaculation (9.7 ± 4.2 cm/s, 7.3 ± 2.7 cm/s, and 8.0 ± 1.1 cm/s, respectively; all $P < .01$). As a corollary, the left TV was significantly smaller than the right one, irrespective of the mathematical formula used (all $P < .0001$), with a median difference of 1.1 [0.9-1.3] ml using the ellipsoid formula.

3.3 | Correlations between scrotal CDUS and clinical parameters

Age was positively associated with mean US-measured TV, irrespective of the mathematical formula used (ellipsoid, $r = 0.143$; Lambert's, $r = 0.142$; Hansen's, $r = 0.126$; all $P < .05$) and epididymal tail size ($r = 0.176$, $P < .05$); however, after adjusting for confounders, the aforementioned relationships were not confirmed (not shown). After adjusting for confounders, pulse pressure was negatively associated with mean US-measured TV (Figure 2, panel A). Conversely, systolic, diastolic, and mean blood pressure, as well as being hypertensive, were not associated with mean US-TV (not shown). Waistline was negatively associated with intratesticular and deferential arteries PSV (Figure 2, panels B and C) and positively with epididymal tail inhomogeneity (Figure 2, panel D). Accordingly, obese subjects ($\text{BMI} \geq 30 \text{ kg/m}^2$) showed a higher prevalence of epididymal tail inhomogeneity, as compared to the rest of the sample (Figure 2, panel E). No difference in scrotal CDUS parameters was observed comparing subjects with and without MetS (not shown). Current smoking was associated with lower testicular and deferential arteries PSV (Figure 2, panel F and G) and alcohol consumption with a larger

TABLE 2 Reference range and mean/median values and percentages of the testicular color Doppler ultrasound (CDUS) parameters in healthy, fertile men

Testis US parameters (n = 248)	Mean/median values and percentages	Reference range
Testicular diameters (mm)		
Right testis length (longitudinal diameter)	45.7 ± 4.3	38.5-52.0
Right testis width (transversal diameter)	29.6 ± 2.8	25.0-34.0
Right testis height (anterior-posterior diameter)	25.1 ± 2.9	20.0-30.0
Left testis length (longitudinal diameter)	44.7 ± 4.5	37.0-52.0
Left testis width (transversal diameter)	28.8 ± 2.8	24.0-34.0
Left testis height (anterior-posterior diameter)	24.4 ± 2.8	20.0-29.0
Testicular volume (ml)		
"Ellipsoid" mathematical formula		
Mean	17.2 ± 4.1	11.8-24.4
Right	17.9 ± 4.4	12.0-25.7
Left	16.5 ± 4.1	11.0-24.1
"Lambert" mathematical formula		
Mean	23.5 ± 5.6	16.0-33.0
Right	24.4 ± 6.0	16.4-35.1
Left	22.6 ± 5.6	15.1-32.9
"Hansen" mathematical formula		
Mean	20.4 ± 5.0	13.5-29.4
Right	21.2 ± 5.5	13.2-30.6
Left	19.7 ± 5.2	12.5-28.6
Testicular homogeneity (%)		
Homogeneous (grade 0)	97.2	
Mild inhomogeneity (grade 1)	2.8	
Moderate inhomogeneity (grade 2)	0.0	
Severe inhomogeneity (grade 3)	0.0	
Testis echogenicity (%)		
Normoechoic	97.2	
Hypoechoic	2.8	
Hyperechoic	0.0	
Testicular macrocalcifications (> 3 mm) (%)		
	1.2	
Testicular microcalcifications (1-3 mm) (%) ^a		
Isolated	10.4	
2-4/US scan	6.4	
≥5/US scan (microlithiasis)	0.0	
Dilated rete testis (%)		
	2.0	
Dilated rete testis volume (ml; ellipsoid formula)		
	0.20 [0.19-0.23]	0.19-0.23
Parenchymal cysts (%)		
	1.2	
Parenchymal cyst longitudinal diameter (mm)		
	3.0 ± 1.0	2.0-4.0
Hypoechoic micronodular lesion (spermatocoele) (%)		
	0.4	
Testicular appendix (Morgagni's hydatid) (%)		
	12.5	
Testicular appendix size (longitudinal diameter) (mm)		
	5.3 ± 0.8	4.0-7.0
Hydrocele (%)		
	4.0	
Hydrocele volume (ml; ellipsoid formula)		
	0.90 [0.20-1.55]	0.20-1.55
Extra-testicular calcifications (%)		
	4.0	

(Continues)

Table 2 (Continued)

Testis US parameters (n = 248)	Mean/median values and percentages	Reference range
Extra-testicular calcifications mean size (mm)	3.0 ± 0.8	1.5-3.8
Testis CDUS parameters		
Testicular artery		
Mean PSV (cm/s)	9.0 ± 3.0	3.0-11.0
Mean acceleration (m/s ²)	0.70 ± 0.11	0.47-0.84
Mean RI	0.58 ± 0.12	0.40-0.83
Mean PI	1.47 ± 0.69	1.00-1.68
Intratesticular arteries (recurrent branch of centripetal arteries)		
Mean PSV (cm/s)	5.7 ± 1.1	3.7-7.0
Mean acceleration (m/s ²)	0.41 ± 0.11	0.23-0.63
Mean RI	0.58 ± 0.17	0.43-0.75
Mean PI	0.92 ± 0.30	0.53-1.53

Note: Data were expressed as mean ± SD when normally distributed, as medians (quartiles) for parameters with non-normal distribution, and as percentages when categorical. The reference range of each testicular parameter has been estimated according to the CLSI Guidelines²⁷ as the 5th and the 95th percentiles of its distribution.

Abbreviations: CDUS, color Doppler ultrasound; PI, pulsatility index; PSV, peak systolic velocity; RI, resistive index; US, ultrasound.

^aMicrocalcifications were localized: 32% in the upper third, 32% in the middle third and 36% in the lower third of the testis.

epididymal head (Figure 2, panel H), while physical activity showed no correlations with scrotal CDUS parameters.

After adjusting for confounders, no association between scrotal CDUS parameters and time to pregnancy, number of children, or history of miscarriage was observed (not shown).

3.4 | Correlations between scrotal CDUS and physical examination (PE) parameters

Prader orchidometer (PO)-assessed TV was positively associated with US-derived TV using ellipsoid, Lambert's and Hansen's formulas (Figure 3, panels A-C), the former showing the highest correlation coefficient. The median difference between PO- and US-derived TV was 3.2 [2.0-4.3], 0.2 [0.1-1.7] and 3.3 [1.6-5.3] ml using ellipsoid, Hansen's, and Lambert's formula, respectively. Notably, Lambert's formula-derived TV (23.5 ± 5.6 ml; Table 2) overestimated the PO-assessed TV (20.4 ± 4.0 ml; see reference #7). Physical examination (PE) identified 20% of the cysts of the epididymal head detected by US, reported in Table 2, in particular when they were > 5 mm. In addition, PE identified 50% and 14% of US-detected dilated epididymal head, defined for a size > 12 mm (considering the entire sample, n = 248) or > 11.5 mm (considering only subjects without cysts, n = 151), respectively. Furthermore, PE identified 37.5% of US-detected dilated epididymal tails, defined for a size > 6 mm (see Table 2), in particular when they were > 6.5 mm. Vas deferens were detected in all subjects both at clinical and US evaluation (concordance of 100%). Finally, PE was able to identify 88% of any US-detected varicocele, while subjects with a clinical grade II and III varicocele represented 92% of those with a severe CDUS-detected

varicocele (grade IV and V according to Sarteschi et al²⁰/Liguori et al²¹ classifications⁴).

3.5 | Correlations between scrotal CDUS and biochemical parameters

After adjusting for confounders (age, waistline, lifestyle and # EAA Centers), mean TV was negatively associated with FSH and LH levels (Figure 3, panels D and E), but not with other hormonal (including testosterone and cFT levels) and glycometabolic parameters (not shown). No associations between other testicular, epididymal, and deferential CDUS features and biochemical parameters were observed. Considering varicocele, subjects with severe varicocele (grade IV and V) showed higher LH levels (Figure 3, panel F), but no difference in other biochemical parameters (including FSH and testosterone levels), when compared with the rest of the sample. The aforementioned associations were confirmed even after introducing cFT in the adjusted model as a further covariate (not shown).

3.6 | Correlations between scrotal CDUS and seminal parameters

After adjusting for confounders (age, waistline, lifestyle, cFT levels, and # EAA Centers), mean TV was positively associated with sperm concentration and total count (Figure 4, panels A and B), but not with other seminal parameters (not shown). Subjects with testicular inhomogeneity showed a lower sperm vitality compared with the rest of the sample (Figure 4, panel C), while those with any parenchymal

TABLE 3 Reference range and mean/median values and percentages of epididymal, deferential and pampiniform plexus color Doppler ultrasound (CDUS) parameters in healthy, fertile men

Epididymal and vas deferens grayscale US parameters	Mean/median values and percentages	Reference range
Epididymal head diameter (including men with cysts) (mm)	9.5 ± 1.5	6.9-12.0
Epididymal head diameter (excluding men with cysts) (mm) (n = 173)	9.0 ± 1.5	7.0-11.5
Epididymal body diameter (mm)	3.8 ± 0.8	2.5-5.0
Epididymal tail diameter (mm)	4.8 ± 0.7	4.0-6.0
Vas deferens diameter (mm)	3.5 ± 0.7	2.3-4.5
Epididymal head echotexture		
Homogeneous (%)	75.0	
Inhomogeneous (%)	25.0	
Epididymal head cysts (%)		
Bilateral (%)	8.0	
>10 mm (%)	3.6	
Largest cyst diameter (d; mm) / volume (v; ml)	d:15.0; v: 2.0	
Epididymal head appendix (%)	3.6	
Epididymal head appendix longitudinal diameter (mm)	2.2 ± 0.6	1.5-3.0
Epididymal tail echotexture		
Homogeneous (%)	80.4	
Inhomogeneous (%)	19.6	
Normoechoic (%)	95.6	
Hyperechoic (%)	2.8	
Hypoechoic (%)	1.6	
Coarse calcifications (%)	0.0	
Epididymal body or tail, or vas deferens cysts	0.0	
Epididymal CDUS parameters		
Head (branch of the testicular artery)		
Mean PSV (cm/s)	4.2 ± 0.6	3.1-4.6
Mean acceleration (m/s ²)	0.31 ± 0.12	0.14-0.50
Mean RI	0.58 ± 0.16	0.30-0.70
Mean PI	0.86 ± 0.28	0.38-1.17
Tail (deferential artery)		
Mean PSV (cm/s)	5.5 ± 1.6	1.8-8.0
Mean acceleration (m/s ²)	0.45 ± 0.9	0.22-0.53
Mean RI	0.64 ± 0.18	0.48-1.00
Mean PI	0.94 ± 0.21	0.70-1.35
Hyperemia ^a (%)	0.8	
Pampiniform plexus US parameters		
Mean LV and ISV size at rest (mm)	LV 2.0 ± 1.0; ISV 1.7 ± 1.0	LV 1.0-3.9; ISV 0.7-3.6
Mean LV and ISV size in men with no varicocele at rest (mm)	LV 1.3 ± 0.6; ISV 1.0 ± 0.5	LV 1.0-2.4; ISV 0.7-2.1
Mean LV and ISV size in men with any varicocele at rest (mm)	LV 3.8 ± 0.5; ISV 3.6 ± 0.5	LV 3.2-4.8; ISV 3.1-5.0
Mean LV and ISV size in men with any varicocele during Valsalva (mm)	LV 4.2 ± 0.5; ISV 4.0 ± 0.5	LV 3.6-5.2; ISV 3.5-5.4
Mean LV and ISV size in men with 1-3 grade varicocele at rest (mm)	LV 3.4 ± 0.2; ISV 3.3 ± 0.1	LV 3.1-3.7; ISV 3.2-3.4
Mean LV and ISV size in men with 1-3 grade varicocele during Valsalva (mm)	LV 3.8 ± 0.2; ISV 3.7 ± 0.1	LV 3.5-3.9; ISV 3.6-3.8
Mean LV and ISV size in men with 4-5 grade varicocele (mm) at rest	LV 3.9 ± 0.5; ISV 3.8 ± 0.5	LV 3.2-5.3; ISV 3.1-4.1
Mean LV and ISV size in men with 4-5 grade varicocele during Valsalva (mm)	LV 4.3 ± 0.5; ISV 4.1 ± 0.5	LV 3.6-5.7; ISV 3.5-5.6

(Continues)

Table 3 (Continued)

Epididymal and vas deferens grayscale US parameters	Mean/median values and percentages	Reference range
Veins extended to the upper testis pole (%)	25.2	
Veins extended to the lower testis pole (%)	18.4	
Varicocele / pampiniform plexus CDUS parameters		
Left side varicocele (%)	37.2	
Grade I	0.0	
Grade II	12.8	
Grade III	6.0	
Grade IV	16.0	
Grade V	2.4	
Right side varicocele (%)	3.2	
Grade I	2.8	
Grade II	0.4	
Grade III	0.0	
Grade IV	0.0	
Grade V	0.0	
Bilateral varicocele (%)	3.2	
“Severe” varicocele ^b (grade IV and V ^c) (%)	18.4	
Continuous venous reflux velocity (cm/s) in “severe” varicocele at rest	4.7 ± 2.2	2.0-10.0
Subclinical varicocele (left side) (%)	3.2	
Subclinical varicocele (right side) (%)	16.0	

Note: Data were expressed as mean ± SD when normally distributed, as medians (quartiles) for parameters with non-normal distribution, and as percentages when categorical. The reference range of each testicular parameter has been estimated according to the CLSI Guidelines²⁷ as the 5th and the 95th percentiles of its distribution.

Abbreviations: CDUS, color Doppler ultrasound; PSV, peak systolic velocity; RI, resistive index; PI, pulsatility index; LV, largest vein¹⁸; ISV, internal spermatic vein²²US, ultrasound.

^aHyperemia was defined as a “diffuse enhanced vascularization”.^{4,17}

^b“Severe” varicocele was defined as venous vessel dilation (> 3 mm) characterized by a continuous venous reflux at rest, increasing or not during a Valsalva manoeuvre^{4,23} (see the main text).

^cGrade IV and V CDUS varicocele according to Sarteschi et al²⁰/Liguori et al²¹ classifications (essentially overlapping, according to reference #4).

calcification had lower sperm concentration and total count (Figure 4, panels D and E). Finally, intratesticular artery PSV was positively associated with sperm normal morphology (Figure 4, panel F).

Epididymal head and vas deferens mean sizes were positively associated with sperm normal morphology and progressive motility, respectively (Figure 5, panels A and B). Subjects with MAR test ≥ 1% showed a higher prevalence of epididymal tail echotexture inhomogeneity (Figure 5, panel C), and a higher mean size of vas deferens and of epididymal body and tail (Figure 5, panels D-F), as compared with the rest of the sample.

No difference in seminal parameters was found comparing subjects with and without any degree of varicocele or even severe CDUS varicocele (not shown).

4 | DISCUSSION

The “EAA ultrasound study”¹³ is the first study aimed at identifying the reference range of the CDUS parameters of human MGT, as

derived from a cohort of healthy, fertile men. In fact, the “EAA ultrasound study” investigated a multinational cohort of 248 healthy, fertile men, which showed semen parameters consistent with those reported by the WHO¹⁴ for fertile men, therefore representing a valid reference for assessing MGT-CDUS normative parameters.¹³ In the present study, we have assessed and reported the reference range and the echotexture and vascular characteristics of the scrotal CDUS parameters investigated in healthy, fertile men. In addition, we have reported and discussed the correlations of the scrotal CDUS parameters with clinical, seminal, and biochemical characteristics of the enrolled cohort, evaluated on the same day and described separately.¹³

Investigator meetings organized by the EAA multicentric consortium before enrolling and evaluating healthy, fertile men¹³ led to the definition of the Standard Operating Procedures (SOPs) for the assessment of scrotal CDUS qualitative and quantitative parameters. They have been discussed extensively on the EAA website (<http://www.andrologyacademy.net/studies12>) and here reported in the Methods section of this manuscript. The careful methodological

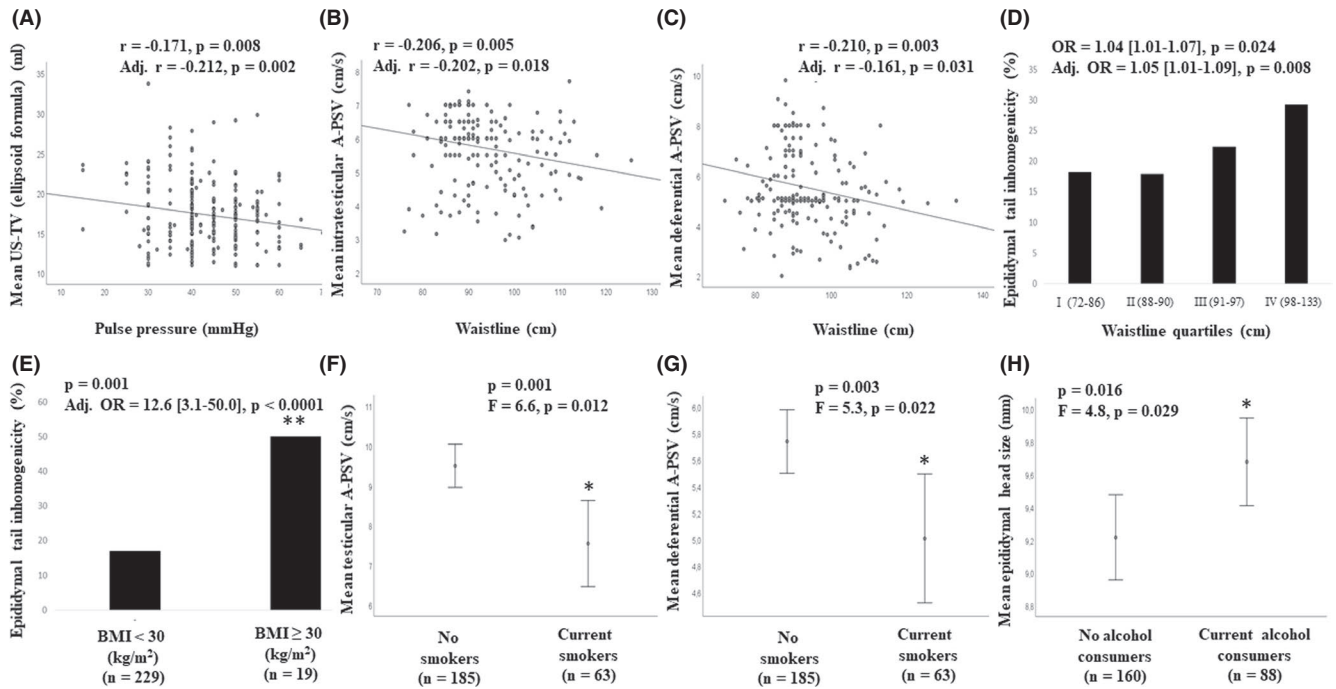


FIGURE 2 Associations between scrotal color Doppler ultrasound (CDUS) and clinical parameters. Panel (A) association between pulse pressure and mean ultrasound-derived testicular volume (US-TV). Panels (B and C) associations between waistline and mean intratesticular (panel B) and deferential (panel C) arteries peak systolic velocity (A-PSV). Panel (D) association between waistline (reported as quartiles for graphical purposes) and epididymal tail inhomogeneity. Panel (E) comparison of the prevalence of epididymal tail inhomogeneity between obese subjects ($\text{BMI} \geq 30 \text{ kg}/\text{m}^2$) and the rest of the sample. Panels (F and G) comparison of testicular (panel F) and deferential (panel G) arteries peak systolic velocity (A-PSV) between current smokers and non-smokers. Panel H: comparison of mean epididymal head size between current alcohol consumers and the rest of the sample. Panel (A) unadjusted and adjusted (for male age, waistline, smoking habit, alcohol consumption, physical activity, cFT levels and # EAA Centers) associations have been reported. Panels (B-E) Unadjusted and adjusted (for male age, smoking habit, physical activity, cFT levels and # EAA Centers) comparisons have been reported. Panels (F and G) unadjusted and adjusted (for male age, waistline, alcohol consumption, cFT levels and # EAA Centers). Panel (A) unadjusted and adjusted (for male age, waistline, smoking habit, physical activity, cFT levels and # EAA Centers) associations have been reported. OR = odds ratio. * $P < .05$; ** $P < .0001$

workout and the agreement reached by the sonographers of the different Centers of the EAA US consortium are reflected by the high inter- and intra-operator comparability. In fact, we found a relatively low coefficient of variation (< 10)²⁶ and a high concordance rate for quantitative and qualitative scrotal CDUS parameters according to the National Association of Testing Authorities (NATA) criteria.²⁵ In our opinion, following the CDUS SOPs proposed by the EAA US consortium in clinical practice will help in reducing the operator-dependent differences among sonographers.

TV is an essential parameter in clinical practice, reflecting not only the seminal and hormonal status of the subject but also the presence of congenital or acquired previous or current testicular or systemic disorders.¹⁻⁵ In this study, we report the reference range of US-derived TV according to the most frequently used mathematical formulas (ellipsoid, Lambert's and Hansen's).^{4,15} Of note, the reference range of testicular diameters has been reported too, according to a previous study.¹⁵ Their values are available in the EAA US database, allowing for the possibility to calculate the TV with any possible mathematical formula and to compare the EAA cohort of healthy, fertile men to any other cohort of fertile or infertile men of previous or future studies. This is relevant, since comparing clinical and CDUS

features of fertile and infertile men in such a systematic way could help in filling in the gap of undiagnosed male infertility, representing, so far, half of the cases of male infertility.^{1,3,4}

In clinical practice, TV is usually assessed by Prader's orchidometer (PO).^{1,4} However, orchidometry overestimates TV when compared to US.²⁸⁻³² PO- and US-derived TV are closely related, both in boys²⁴ and in adult eugonadal or hypogonadal^{28-30,32} subjects. However, US offers a greater accuracy in TV measurement than PO.^{29,33,34} In the present study, the aforementioned close relationship between PO- and US-derived TV is confirmed and reported, for the first time, in healthy, fertile men. US-assessed TV varies according to the mathematical formula applied (eg ellipsoid, Lambert's, Hansen's); however, the results are similar among different ethnic groups.^{15,29,35,36} The best mathematical formula to calculate US-derived TV is currently being debated.^{15,31,37} Recently, the European Society of Urogenital Radiology (ESUR)^{18,19} supported the use of Lambert's formula, considered the most accurate according to previous studies,^{34,38-40} however without a "strong" consensus.¹⁸ In the present study, the US-TV calculated with the ellipsoid formula showed the most accurate correlation with the PO-assessed TV, while Lambert's formula-derived TV overestimated the PO-assessed

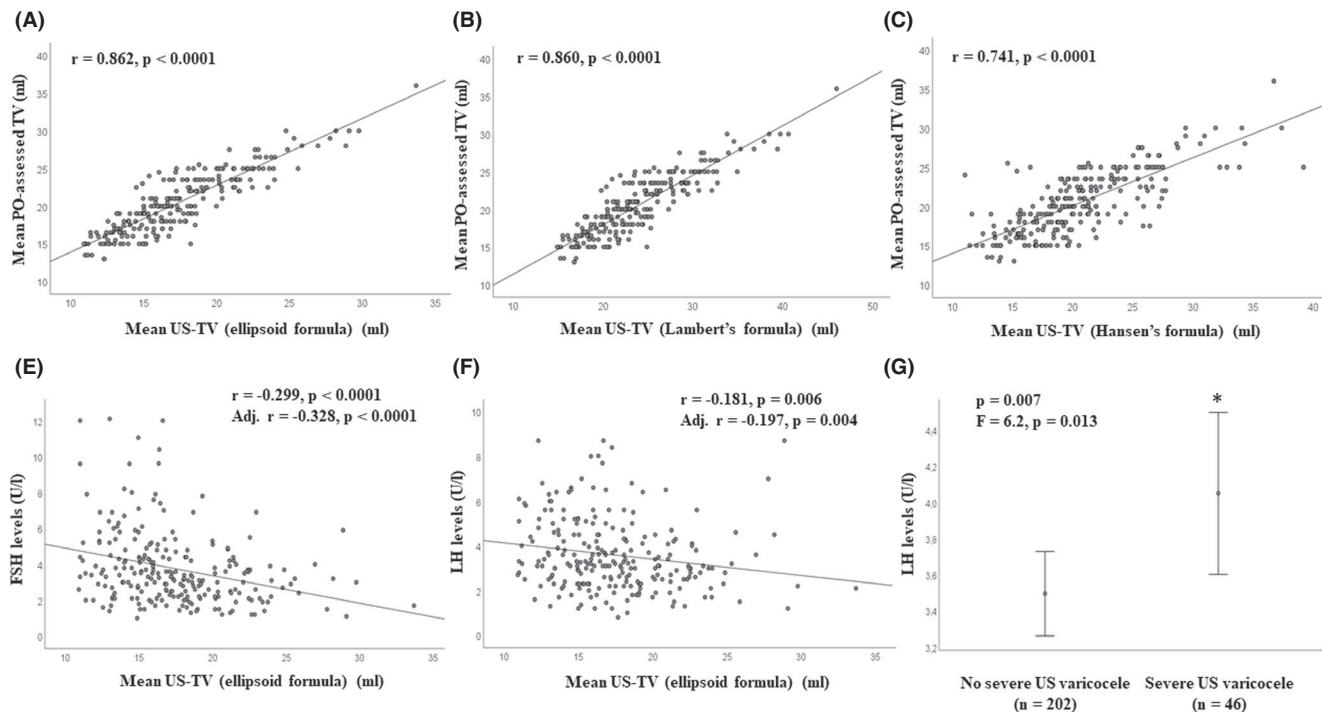


FIGURE 3 Associations between scrotal color Doppler ultrasound (CDUS), physical examination (PE) and hormonal parameters. Panels (A-C) associations between mean ultrasound-derived testicular volume (US-TV), according to different mathematical formulas (panel A, ellipsoid; panel B, Lambert's; panel C, Hansen's) and mean Prader orchidometer (PO)-assessed TV. Panels (D and E) associations between mean ultrasound-derived testicular volume (US-TV), FSH (panel D) and LH (panel E) levels. Panel (F) comparison of LH levels between subjects with "severe" varicocele (grade IV and V varicocele according to Sarteschi et al¹⁴/Liguori et al¹⁵ classifications⁴) and the rest of the sample. Panels (D-F) unadjusted and adjusted (for male age, waistline, smoking habit, alcohol consumption, physical activity and # EAA Centers) associations have been reported. * $P < .05$

TV. According to the aforementioned considerations, the fact that most of the published studies report TV using the ellipsoid formula⁴ and that most of the US softwares automatically calculate TV with the ellipsoid formula, the results of the present study have been discussed below considering the ellipsoid formula-derived TV.

The median difference between PO- and US-derived TV was ~ 3 ml. So far, the mean TV difference reported comparing US and PO was 4-5 ml.^{33,41,42} Using the ellipsoid formula, a median TV of ~ 14 ml was reported in healthy German,⁹ Danish,²⁹ and South Korean³⁵ men, a mean TV of ~ 15 ml in young Italian men³⁶ and of ~ 19 ml in fertile Italian men.⁴³⁻⁴⁵ Conversely, an average US-detected TV in infertile patients ranges from ~ 10 ml to ~ 15 ml.^{29,33,43,44} In the present study, a mean TV of ~ 17 ml in healthy, fertile men was found. The left TV was smaller than the right one according to some,^{6,15,29,46} but not all,³⁵ the previous studies. In this study, the US-measured TV lowest reference limit for right and left testis was 12 and 11 ml, respectively. This is relevant, because below these thresholds "testicular hypotrophy" can now be defined in an evidence-based way. Until now, a TV < 12 ml had been proposed to indicate testicular hypotrophy at US using the ellipsoid formula^{47,48} or irrespective of the mathematical formula used,⁴⁹ however without evidence-based data. Previously, a TV < 10 ml using the Lambert's formula was reported to be associated with testicular dysfunction, however evaluating only Japanese men with infertility.^{42,50}

In our cohort, after adjusting for confounders, we found no association between mean TV and age. Previous clinical studies reported a decrease^{51,52} or a stable⁵³⁻⁵⁵ TV over time, with a significant reduction in TV only in the eighth decade of life.^{56,57} However, some authors have suggested a mild TV decline starting from the fifth decade.^{15,32} The lack of association between age and mean TV in our cohort could depend on the limited age range (23-53 years) considered and to the specific characteristics (healthy, fertile men) of the population studied. In our cohort, mean US-TV was negatively associated with pulse pressure, in line with the results reported in a previous EAA study considering PO-derived TV.¹³ Data supporting the negative relationship between pulse pressure and mean TV have been extensively discussed in a previous study.¹³ However, some authors reported a positive association between mean³² or systolic⁵⁸ blood pressure and mean TV, although in populations (infertile men and adolescents, respectively) with different characteristics than that investigated in this study. Hence, the relationship between blood pressure and TV needs further investigation.

We here report that mean US-TV in fertile men is positively associated with sperm concentration and total sperm count and negatively with FSH and LH levels. Previous studies reported that US-estimated TV was positively related to total sperm count,^{6,29,42,59,60} sperm motility,^{6,42} normal sperm morphology,^{6,29} and testosterone levels,^{6,32,42} and negatively correlated with LH and FSH.^{6,42,61} A

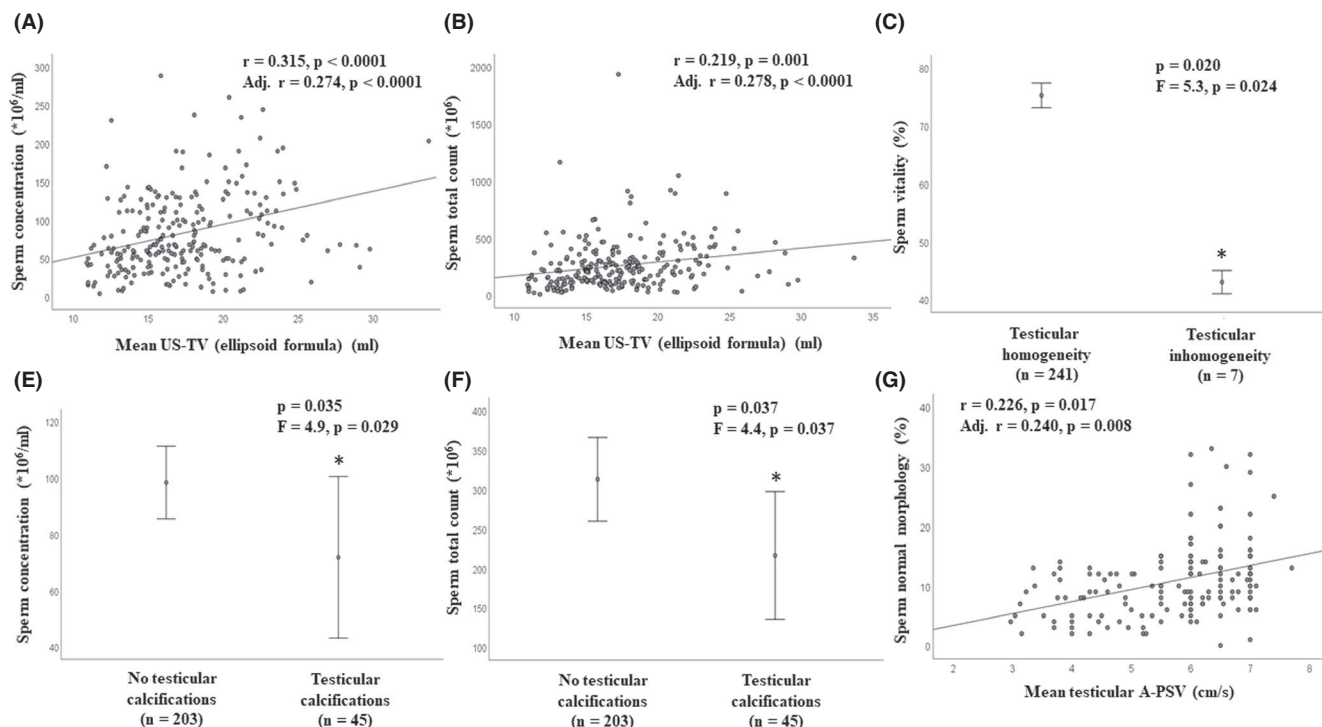


FIGURE 4 Associations between testicular color Doppler ultrasound (CDUS) and seminal parameters. Panels (A, B) associations between mean ultrasound-derived testicular volume (US-TV) and sperm concentration (panel A) or total count (panel B). Panel (C) comparison of sperm vitality between subjects with testicular inhomogeneity and the rest of the sample. Panels (D and E) comparison of sperm concentration (panel D) or total count (panel E) between subjects with testicular calcifications and the rest of the sample. Panel (F) association between testicular artery peak systolic velocity (A-PSV) and sperm normal morphology. Unadjusted and adjusted (for male age, waistline, smoking habit, alcohol consumption, physical activity, cFT levels and # EAA Centers) associations have been reported. * $P < .05$

negative correlation between US-TV and non-conventional sperm parameters (sperm DNA fragmentation,^{47,62,63} percentage of spermatozoa with low mitochondrial membrane potential, phosphatidylserine externalization, or chromatin compactness^{62,63}) has been also reported.

In our cohort, only a very few subjects showed testicular echotexture inhomogeneity, always of a mild degree. Testicular inhomogeneity was originally studied and classified by Danish (Lenz et al)²⁹ and Swedish (Westlander et al)⁶⁴ physicians, who proposed a five-point scale classification. In addition, Lenz et al²⁹ proposed a five-point “testicular echotexture score,” based on testicular inhomogeneity, ranging from 0 (regular pattern) to 5 (tumor suspected), that correlated negatively with normal sperm morphology,²⁹ sperm count,⁵⁹ US-TV^{29,59,65} and positively with the presence of a *carcinoma in situ*⁶⁵. Recently, Pozza et al⁶ developed, in a cohort of 2230 men, a semi-quantitative, multiparametric (including bilateral US-TV, echotexture, echogenicity and microlithiasis) score, ranging from 0 to 7 and named “testicular ultrasound (TU) score,” that has proved significantly more accurate than Lenz’s score²³ in predicting impaired spermatogenesis, and able to predict hypogonadism. The EAA US consortium proposes here a new, four-point scale classification of testicular inhomogeneity, easy to use in clinical practice and avoiding the term “suspected tumors.” In fact, advanced US technology—both in terms of image quality and resolution—leads to a more careful characterization of “suspected tumors,” nowadays described

as “nodular lesions” and no more as “echotexture abnormalities”.^{4,5,7} In previous studies, testicular inhomogeneity was associated with atrophy and fibrosis,⁶⁶ advanced age,²⁹ testicular function impairment,^{29,67} impaired sperm quality and azoospermia,⁶⁸ abnormal sperm morphology,^{29,69} and several other pathological conditions in infertile men.⁴ We here report that fertile men with mild testicular inhomogeneity only showed a lower sperm vitality, when compared to the rest of the sample. Considering other echotexture abnormalities, in our cohort testicular microlithiasis was not detected, while calcifications, isolated or scanty (< 5/US scan), were present in about one out of five men, which showed a lower sperm concentration than the rest of the sample. Currently, the association between testicular microlithiasis and infertility is debated,^{49,70-72} while no study has focused on isolated or limited testicular calcifications. Furthermore, a dilated rete testis, considered a sign of downstream obstruction,⁷³ was rarely detected in our cohort and, when observed, was described as mild. Finally, no nodular lesions suspected to be tumors were observed in fertile men.

In this study, we report, for the first time in fertile men, a reference range for several blood flow parameters related to testicular and intratesticular arteries. The reference range of the testicular artery PSV and testicular/intratesticular RI are in line with the mean or median values reported in previous studies performed on the general population.^{15,74} Increased testicular artery PSV and RI have been associated with orchitis^{17,75} and spontaneous detorsion

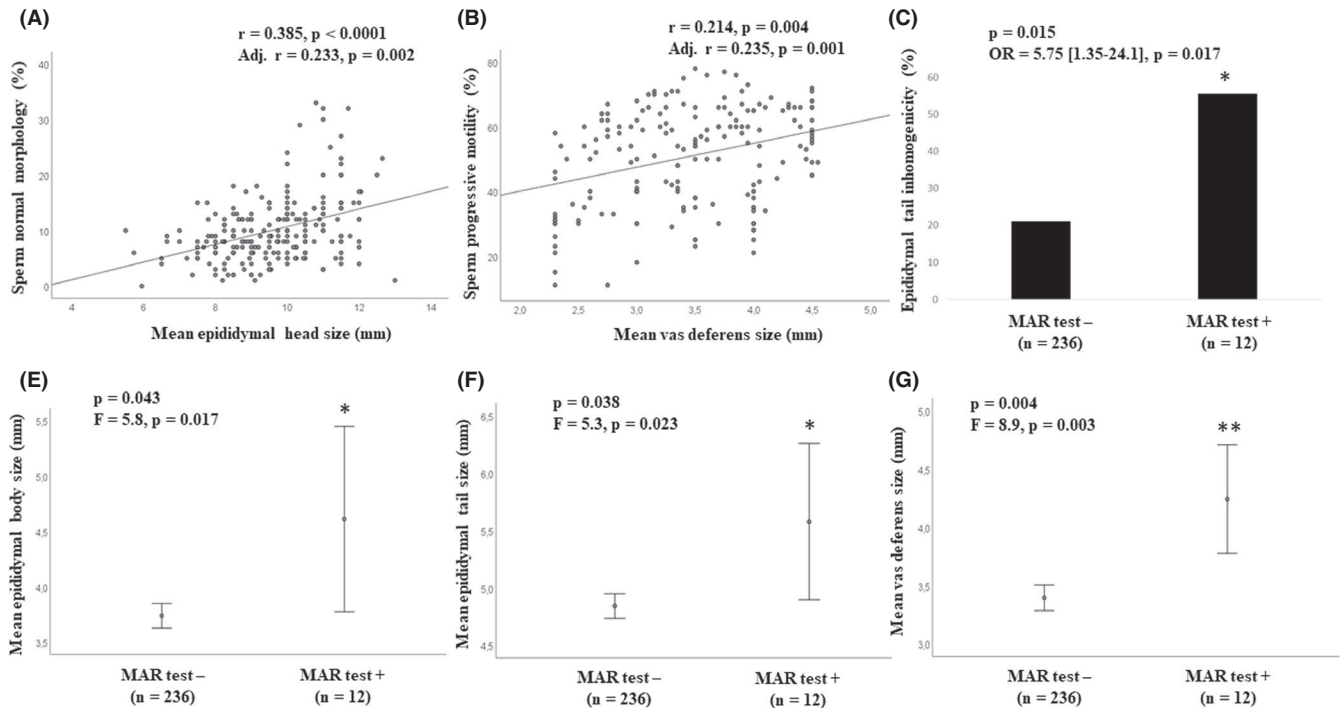


FIGURE 5 Associations between epididymal and deferential color Doppler ultrasound (CDUS) and seminal parameters. Panel (A) association between mean epididymal head size and sperm normal morphology. Panel (B) association between mean vas deferens size and sperm progressive motility. Panels (C-F) comparison between subjects with positive ($\geq 1\%$) and negative MAR test for the prevalence of epididymal tail inhomogeneity (panel C), epididymal body (panel D) and tail (panel E) and vas deferens (panel F) size. Unadjusted and adjusted (for male age, waistline, smoking habit, alcohol consumption, physical activity, cFT levels and # EAA Centers) associations have been reported. OR = odds ratio. * $P < .05$; ** $P < .005$

following testicular torsion,⁷⁶ often leading to testicular damage,^{4,17} while a reduced testicular arterial blood flow has been suggested to reflect impaired microcirculation and spermatogenesis⁷⁴ and has been associated with varicocele by some authors.⁷⁷ On the other hand, an increased intratesticular RI has been associated with increased FSH levels,⁷⁸ reduced sperm count,⁷⁹ and varicocele.⁸⁰ In our study, we found no associations between testicular/intratesticular RI and clinical, seminal, or biochemical parameters. Conversely, we found that testicular artery PSV was lower in current smokers, while intratesticular artery PSV was associated positively with normal sperm morphology and negatively with increased waist circumference. The latter observation suggests a possible new mechanism linking obesity/metabolic syndrome and poor sperm morphology, along with elevated blood pressure, as previously described.⁶⁹ The aforementioned data support the relevance of assessing testicular vascularization, which, at present, is essentially evaluated mainly for research purposes.^{4,74}

The reference range of epididymal segments and vas deferens have been reported here. Previously, a “normal size” of epididymal segments had been proposed by some authors (see, for review, reference #4), however without being evidence-based, while vas deferens normal values have never been reported. The highest reference limit observed in fertile men for epididymal head is 12 mm in subjects with cysts and 11.5 mm in those without. The highest reference limit for epididymal tail is 6 mm. Notably, some authors,⁸¹ in azoospermic men with normal serum FSH, reported

that an epididymal head ≥ 10.85 mm was predictive of obstruction, while others⁸² proposed that an epididymal head > 12 mm and a tail > 6 mm are abnormal and associated with male accessory gland infection. In the present cohort, an increased epididymal size and a tail dilation are associated with the presence of a positive MAR test, suggesting damage to the blood-epididymal barrier, according to a previous study on fertile and infertile men.⁴⁵ In addition, in the present study, a larger epididymal head size was observed in alcohol consumers, a finding of difficult interpretation. The US reference range for epididymal and vas deferens size, along with an evidence-based cutoff defining their dilation, can increase diagnostic accuracy of distal obstruction (along with other prostate-vesicular US signs) and of chronic or acute inflammation.⁴ As a corollary, the present results show that epididymal head size and arterial supply (represented by the testicular artery PSV, supplying epididymal head with its branches) and vas deferens size, within the normal ranges, were positively associated with normal sperm morphology and progressive motility, respectively, suggesting a role for these ductal structures in favouring sperm quality.^{83,84}

The presence of epididymal head cysts has been observed in about one out of three fertile men, with a maximum size of 15 mm, suggesting a minor, if any, role for these cysts in male infertility.^{4,85} Similar considerations can be drawn for epididymal inhomogeneity, since it was found in one out of four/five fertile men, although it is believed to be associated with acute or chronic inflammation.^{4,17,82,86,87} However, epididymal inhomogeneity could reflect

a general inflammatory state, as supported in this study by an increasing prevalence of epididymal inhomogeneity as a function of increasing waistline and its high prevalence in obese men, as both conditions are characterized by a low grade inflammation.^{88,89} Similarly, an association between metabolic syndrome/increased waistline and testicular inhomogeneity has been previously reported,⁶⁹ but not observed in this survey. This is most probably due to the low prevalence of subjects with testicular inhomogeneity in our cohort. However, we here report a negative association between increased waist circumference and decreased intratesticular and deferential artery PSV, suggesting a possible role of central adiposity in testicular and epididymal arterial hypoperfusion. It is important to note that neither obesity nor increased waist circumference are associated with alterations of conventional sperm parameters in the "EAA ultrasound study" cohort.¹³

Finally, in this study we report the reference range of pampiniform plexus along with the prevalence and characteristics of varicocele in fertile men. CDUS showed a higher accuracy than physical examination in detecting varicocele, in line with previous studies (see, for review, reference #4). A high prevalence of any CDUS-detected varicocele (37.2%) and of severe varicocele (18.4%) was observed, in line with the clinical data previously reported.¹³ In fact, the prevalence of varicocele was similar to that reported in primary infertile men.^{18,19} Considerations on the scanty impact of varicocele on male infertility and avoiding uncritical varicolectomy have been extensively discussed in the clinical introductory report of the "EAA ultrasound study".¹³ In our cohort, subjects with severe varicocele showed higher LH (but not testosterone) levels than the rest of the sample, suggesting mild impairment in androgen secretion. However, the present data do not support a link between severe varicocele and compensated hypogonadism, since LH levels in the present cohort are in the normal range according to a previous study.⁹⁰

5 | CONCLUSIONS

The present study investigates a multinational cohort of 248 healthy, fertile men with semen parameters consistent with those reported by the WHO,⁸ representing a valid reference point for assessing MGT-CDUS normative parameters.⁷ The CDUS reference range and characteristics of the scrotal organs of healthy, fertile men have been reported here. CDUS showed a higher accuracy than physical examination in detecting scrotal abnormalities. PO- and US-derived TV were closely related. The US-assessed TV with the ellipsoid formula showed the best correlation with the PO-assessed TV. The mean TV of healthy, fertile men was ~ 17 ml. The lowest reference limit for right and left testis was 12 and 11 ml, respectively, representing a threshold for defining "testicular hypotrophy." The highest reference limit for epididymal head and tail and vas deferens was 12, 6, and 4.5 mm, respectively. Mean TV was associated positively with sperm concentration and total count and negatively with FSH and LH levels and pulse pressure. Subjects with testicular inhomogeneity or calcifications showed lower sperm vitality and concentration,

respectively, than the rest of the sample. Sperm normal morphology and progressive motility were positively associated with epididymal head size/arterial supply and vas deferens size, respectively. Increased epididymis and vas deferens sizes were associated with MAR test positivity. Decreased epididymal tail homogeneity/arterial supply was positively associated with waistline, which, in turn, was negatively associated with intratesticular vascularization. CDUS-detected varicocele showed a relatively high prevalence in this cohort, similar to that reported in primary infertile men, without any relevant association with seminal or hormonal parameters, suggesting its scanty effect on male fertility. No association between scrotal CDUS parameters and time to pregnancy, number of children or history of miscarriage was observed. The present findings in fertile men will help in better understanding the pathophysiology of sperm abnormalities and male infertility, underlying modifications in their management (eg treating visceral obesity or avoiding uncritical varicolectomy).

ORCID

F Lotti  <https://orcid.org/0000-0001-8343-1807>

AE Calogero  <https://orcid.org/0000-0001-6950-335X>

AM Isidori  <https://orcid.org/0000-0002-9037-5417>

S La Vignera  <https://orcid.org/0000-0002-7113-2372>

A Pilatz  <https://orcid.org/0000-0001-8072-1841>

O Rajmil  <https://orcid.org/0000-0003-1987-9206>

C Krausz  <https://orcid.org/0000-0001-6748-8918>

REFERENCES

1. Krausz C. Male infertility: pathogenesis and clinical diagnosis. *Best Pract Res Clin Endocrinol Metab.* 2011;25:271-285.
2. Punab M, Poolamets O, Paju P, et al. Causes of male infertility: a 9-year prospective monocentre study on 1737 patients with reduced total sperm counts. *Hum Reprod.* 2017;32:18-31.
3. Lotti F, Maggi M. Sexual dysfunction and male infertility. *Nat Rev Urol.* 2018;15:287-307.
4. Lotti F, Maggi M. Ultrasound of the male genital tract in relation to male reproductive health. *Hum Reprod Update.* 2015;21:56-83.
5. Lotti F, Maggi M. Color-Doppler Ultrasound and New Imaging Techniques in Andrological Examination. In: Simoni M, Huhtaniemi IT, eds. *Endocrinology of the Testis and Male Reproduction*, 1st edn, Chapter 19. Cham, Switzerland: Springer International Publishing AG; 2017:555-622.
6. Pozza C, Kanakis G, Carlomagno F, et al. Testicular ultrasound score: A new proposal for a scoring system to predict testicular function. *Andrology.* 2020;8:1051-1063.
7. Isidori AM, Lenzi A. Scrotal CDU: Morphological and Functional Atlas. Genova: Forum Service Editore s.r.l., 2008.
8. Isidori AM, Pozza C, Gianfrilli D, et al. Differential diagnosis of non-palpable testicular lesions: qualitative and quantitative contrast-enhanced US of benign and malignant testicular tumors. *Radiology.* 2014;273:606-618.
9. Rafailidis V, Robbie H, Konstantatou E, et al. Sonographic imaging of extra-testicular focal lesions: comparison of grey-scale, colour Doppler and contrast-enhanced ultrasound. *Ultrasound.* 2016;24:23-33.
10. Pozza C, Pofi R, Tenuta M, et al. Clinical presentation, management and follow-up of 83 patients with Leydig cell tumors of the testis: a prospective case-cohort study. *Hum Reprod.* 2019;34:1389-1403.

11. Pozza C, Gianfrilli D, Fattorini G, et al. Diagnostic value of qualitative and strain ratio elastography in the differential diagnosis of non-palpable testicular lesions. *Andrology*. 2016;4:1193-1203.
12. European Academy of Andrology. EAA Multicentre Study "Standardization of the male genital tract colour-Doppler ultrasound parameters in healthy, fertile men" <http://www.andrologycademy.net/studies>. Accessed October 16, 2020
13. Lotti F, Frizza F, Balercia G, et al. The European Academy of Andrology (EAA) ultrasound study on healthy, fertile men: clinical, seminal and biochemical characteristics. *Andrology*. 2020;8:1005-1020.
14. World Health Organization. *WHO Laboratory Manual for the Examination and Processing of Human Semen*, 5th edn. Geneva, Switzerland: WHO Press; 2010.
15. Pilatz A, Ruzs A, Wagenlehner F, Weidner W AB. Reference values for testicular volume, epididymal head size and peak systolic velocity of the testicular artery in adult males measured by ultrasonography. *Ultraschall Med*. 2013;34:349-354.
16. Migaleddu V, Virgilio G, Del Prato A, Bertolotto M. Sonographic scrotal anatomy. In: Bertolotto M, Trombetta C (eds). *Scrotal Pathology*. Medical Radiology. Diagnostic Imaging. Springer, 2012, 41-54.
17. Pilatz A, Wagenlehner F, Bschleipfer T, et al. Acute epididymitis in ultrasound: Results of a prospective study with baseline and follow-up investigations in 134 patients. *Eur J Radiol*. 2013;82:e762-768.
18. Freeman S, Bertolotto M, Richenberg J, et al. Derchi LE; members of the ESUR-SPIWG WG. Ultrasound evaluation of varicoceles: guidelines and recommendations of the European Society of Urogenital Radiology Scrotal and Penile Imaging Working Group (ESUR-SPIWG) for detection, classification, and grading. *Eur Radiol*. 2020;30:11-25.
19. Bertolotto M, Freeman S, Richenberg J, et al. ESUR new Ultrasound evaluation of varicoceles: systematic literature review and rationale of the ESUR-SPIWG Guidelines and Recommendations. *J Ultrasound*. 2020;23:487-507.
20. Sarteschi LM, Paoli R, Bianchini M, Menchini Fabris GF. Lo studio del varicocele con eco-color Doppler. *G Ital Ultrasonologia*. 1993;4:43-49.
21. Liguori G, Trombetta C, Garaffa G, et al. Color Doppler ultrasound investigation of varicocele. *World J Urol*. 2004;22:378-381.
22. Orda R, Sayfan J, Manor H, Witz E, Sofer Y. Diagnosis of varicocele and postoperative evaluation using inguinal ultrasonography. *Ann Surg*. 1987;206:99-101.
23. Lotti F, Corona G, Mancini M, et al. The association between varicocele, premature ejaculation and prostatitis symptoms: possible mechanisms. *J Sex Med*. 2009;6:2878-2887.
24. Kroese AC, de Lange NM, Collins J, Evers JL. Surgery or embolization for varicoceles in subfertile men. *Cochrane Database Syst Rev*. 2012;10:CD000479.
25. National Association of Testing Authorities (NATA), Australia. Guidelines for the validation and verification of quantitative and qualitative test methods. <https://www.nata.com.au/> 2018
26. Westgard JO, Barry PL, Quam EF. Basic QC practices: Training in statistical quality control for healthcare laboratories. Madison, WI: Westgard Quality Corporation, 1998. (see at <https://www.westgard.com/lesson34.htm>).
27. Clinical and Laboratory Standard Institute (CLSI) Guidelines C28-A2. How to define and determine reference interval in the clinical laboratory: approved guideline - 2nd edition. Wayne, PA, USA; 2000. Chapter 7. Analysis of Reference Values, pp.13-14.
28. Behre HM, Nashan D, Nieschlag E. Objective measurement of testicular volume by ultrasonography: evaluation of the technique and comparison with orchidometer estimates. *Int J Androl*. 1989;12:395-403.
29. Lenz S, Giwercman A, Elsborg A, et al. Ultrasonic testicular texture and size in 444 men from the general population: correlation to semen quality. *Eur Urol*. 1993;24:231-238.
30. Diamond DA, Paltiel HJ, DiCanzio J, et al. Comparative assessment of pediatric testicular volume: orchidometer versus ultrasound. *J Urol*. 2000;164:1111-1114.
31. Goede J, Hack WW, Sijstermans K, van der Voort-Doedens LM, Van der Ploeg T, Meij-de Vries A, Delemarre-van de Waal HA. Normative values for testicular volume measured by ultrasonography in a normal population from infancy to adolescence. *Horm Res Paediatr*. 2011;76:56-64.
32. Rastrelli G, Corona G, Lotti F, Boddi V, Mannucci E, Maggi M. Relationship of testis size and LH levels with incidence of major adverse cardiovascular events in older men with sexual dysfunction. *J Sex Med*. 2013;10:2761-2773.
33. Sakamoto H, Saito K, Ogawa Y, Yoshida H. Testicular volume measurements using Prader orchidometer versus ultrasonography in patients with infertility. *Urology*. 2007;69:158-162.
34. Sakamoto H, Saito K, Oohta M, Inoue K, Ogawa Y, Yoshida H. Testicular volume measurement: comparison of ultrasonography, orchidometry, and water displacement. *Urology*. 2007;69:152-157.
35. Bahk JY, Jung JH, Jin LM, Min SK. Cut-off value of testes volume in young adults and correlation among testes volume, body mass index, hormonal level, and seminal profiles. *Urology*. 2010;75:1318-1323.
36. Foresta C, Garolla A, Frigo AC, et al. Anthropometric, penile and testis measures in post-pubertal Italian males. *J Endocrinol Invest*. 2013;36:287-292.
37. Lin CC, Huang WJ, Chen KK. Measurement of testicular volume in smaller testes: how accurate is the conventional orchidometer? *J Androl*. 2009;30:685-689.
38. Lambert B. The frequency of mumps and of mumps orchitis and the consequences for sexuality and fertility. *Acta Genet Stat Med*. 1951;2(Suppl 1):1-166.
39. Hsieh ML, Huang ST, Huang HC, Chen Y, Hsu YC. The reliability of ultrasonographic measurements for testicular volume assessment: comparison of three common formulas with true testicular volume. *Asian J Androl*. 2009;11:261-265.
40. Mbaeri TU, Orakwe JC, Nwofor AME, Oranusi CK, Mbonu OO. Ultrasound measurements of testicular volume: comparing the three common formulas with the true testicular volume determined by water displacement. *Afr J Urol*. 2013;19:69-73.
41. Carlsen E, Andersen AG, Buchreitz L, et al. Inter-observer variation in the results of the clinical andrological examination including estimation of testicular size. *Int J Androl*. 2000;23:248-253.
42. Sakamoto H, Ogawa Y, Yoshida H. Relationship between testicular volume and testicular function: comparison of the Prader orchidometric and ultrasonographic measurements in patients with infertility. *Asian J Androl*. 2008;10:319-324.
43. Lotti F, Corona G, Castellini G, et al. Semen quality impairment is associated with sexual dysfunction according to its severity. *Hum Reprod*. 2016;31:2668-2680.
44. Lotti F, Corona G, Cocci A, et al. The prevalence of midline prostatic cysts and the relationship between cyst size and semen parameters among infertile and fertile men. *Hum Reprod*. 2018;33:2023-2034.
45. Lotti F, Baldi E, Corona G, et al. Epididymal more than testicular abnormalities are associated with the occurrence of antisperm antibodies as evaluated by the MAR test. *Hum Reprod*. 2018;33:1417-1429.
46. Beres J, Papp G, Pazonyi I, Czeizel E. Testicular volume variations from 0 to 28 years of age. *Int Urol Nephrol*. 1989;21:159-167.
47. Condorelli R, Calogero AE, La Vignera S. Relationship between Testicular Volume and Conventional or Nonconventional Sperm Parameters. *Int J Endocrinol*. 2013;2013:145792.
48. Pedersen MR, Osther PJS, Rafaelsen SR. Ultrasound Evaluation of Testicular Volume in Patients with Testicular Microlithiasis. *Ultrasound Int Open*. 2018;4:E99-E103.
49. Richenberg J, Belfield J, Ramchandani P, et al. Testicular microlithiasis imaging and follow-up: guidelines of the ESUR scrotal imaging subcommittee. *Eur Radiol*. 2015;25:323-330.
50. Sakamoto H, Yajima T, Nagata M, Okumura T, Suzuki K, Ogawa Y. Relationship between testicular size by ultrasonography and testicular function: measurement of testicular length, width, and depth in patients with infertility. *Int J Urol*. 2008;15:529-533.

51. Stearns EL, MacDonnell JA, Kaufman BJ, et al. Declining testicular function with age. *Am J Med.* 1974;57:761-766.
52. Baker HWG, Burger HG, de Kretser DM HB, et al. Changes in the pituitary-testicular system with age. *Clin Endocrinol (Oxf).* 1976;5:349-372.
53. Harman SM, Tsitsouras PD. Reproductive hormones in aging men: I. Measurement of sex steroids, basal luteinizing hormone and Leydig cell response to human chorionic gonadotropin. *J Clin Endocrinol Metab.* 1980;51:35-40.
54. Sparrow D, Bosse R, Rowe JW. The influence of age, alcohol consumption, and body build on gonadal function in men. *Clin Endocrinol Metab.* 1980;51:508-512.
55. Nieschlag E, Lammers U, Freischem CW LK, Wickings EJ. Reproductive functions in young fathers and grandfathers. *Clin Endocrinol Metab.* 1982;55:676-681.
56. Handelsman DJ, Staraj S. Testicular size: the effects of aging, malnutrition, and illness. *J Androl.* 1985;6:144-151.
57. Sartorius GA, Nieschlag E. Paternal age and reproduction. *Hum Reprod Update.* 2010;16:65-79.
58. Kwok MK, Leung GM, Schooling CM. Pubertal testis volume, age at pubertal onset, and adolescent blood pressure: Evidence from Hong Kong's "Children of 1997" birth cohort. *Am J Hum Biol.* 2017;29:4.
59. Lenz S, Thomsen JK, Giwercman A, Hertel NT, Hertz J, Skakkebaek NE. Ultrasonic texture and volume of testicles in infertile men. *Hum Reprod.* 1994;9:878-881.
60. Cooper TG. Semen analysis. In: Nieschlag E, Behre HM, Nieschlag S, eds. *Andrology. Male Reproductive Health and Dysfunction*, 3rd edn. Berlin: Springer; 2010:125-138.
61. Sakamoto H, Ogawa Y. Does a clinical varicocele influence the relationship between testicular volume by ultrasound and testicular function in patients with infertility? *Fertil Steril.* 2009;92:1632-1637.
62. Lotti F, Tamburrino L, Marchiani S, et al. Semen apoptotic M540 body levels correlate with testis abnormalities: a study in a cohort of infertile subjects. *Hum Reprod.* 2012;27:3393-3402.
63. Lotti F, Tamburrino L, Marchiani S, et al. DNA fragmentation in two cytometric sperm populations: relationship with clinical and ultrasound characteristics of the male genital tract. *Asian J Androl.* 2017;19:272-279.
64. Westlander G, Ekerhovd E, Granberg S, et al. Serial ultrasonography, hormonal profile and antisperm antibody response after testicular sperm aspiration. *Hum Reprod.* 2001;16:2621-2627.
65. Lenz S, Skakkebaek NE, Hertel NT. Abnormal ultrasonic pattern in contralateral testes in patients with unilateral testicular cancer. *World J Urol.* 1996;14(Suppl 1):S55-S58.
66. Loberant N, Bhatt S, McLennan GT, Dogra VS. Striated Appearance of the Testes. *Ultrasound Q.* 2010;26:37-44.
67. Behre HM, Kliesch S, Schadel F, Nieschlag E. Clinical relevance of scrotal and transrectal ultrasonography in andrological patients. *Int J Androl.* 1995;18:27-31.
68. Spaggiari G, Granata M, Santi D. Testicular ultrasound inhomogeneity is an informative parameter for fertility evaluation. *Asian J Androl.* 2020;22:302-308.
69. Lotti F, Corona G, Degli Innocenti S, et al. Seminal, ultrasound and psychobiological parameters correlate with metabolic syndrome in male members of infertile couples. *Andrology.* 2013;1:229-239.
70. Rassam Y, Gromoll J, Kliesch S, Schubert M. Testicular Microlithiasis Is Associated with Impaired Spermatogenesis in Patients with Unexplained Infertility. *Urol Int.* 2020;104(7-8):610-616.
71. Barbonetti A, Martorella A, Minaldi E, et al. Testicular Cancer in Infertile Men With and Without Testicular Microlithiasis: A Systematic Review and Meta-Analysis of Case-Control Studies. *Front Endocrinol (Lausanne).* 2019;10:164.
72. Balawender K, Orkisz S, Wisz P. Testicular microlithiasis: what urologists should know. A review of the current literature. *Cent European. J Urol.* 2018;71:310-314.
73. Jungwirth A, Diemer T, Kopa Z, Krausz C, Minhas S, Tournaye H. Guidelines on Male Infertility, European Association of Urology Guidelines. <https://uroweb.org/guideline/male-infertility/> Accessed October 16, 2020.
74. Schurich M, Aigner F, Frauscher F, Pallwein L. The role of ultrasound in assessment of male fertility. *Eur J Obstet Gynecol Reprod Biol.* 2009;144(Suppl 1):S192-S198.
75. Pepe P, Panella P, Pennisi M, Aragona F. Does color Doppler sonography improve the clinical assessment of patients with acute scrotum? *Eur J Radiol.* 2006;60:120-124.
76. Uyeda JW, Gans BS, Sodickson A. Imaging of acute and emergent genitourinary conditions: what the radiologist needs to know. *AJR Am J Roentgenol.* 2015;204:W631-W639.
77. Tarhan S, Gümüş B, Gündüz I, Ayyıldız V, Gökten C. Effect of varicocele on testicular artery blood flow in men—color Doppler investigation. *Scand J Urol Nephrol.* 2003;37:38-42.
78. Battaglia C, Pasini A, Mancini F, Burnelli R, Cognigni A, de Alosvio D. Role of intratesticular ultrasonographic and Doppler flow analyses in evaluating gonadal status in male survivors of childhood malignancy. *Fertil Steril.* 2005;83:1867-1870.
79. Herwig R, Tosun K, Schuster A, et al. Tissue perfusion-controlled guided biopsies are essential for the outcome of testicular sperm extraction. *Fertil Steril.* 2007;87:1071-1076.
80. Unsal A, Turgut AT, Taskin F, Kosar U, Karaman CZ. Resistance and pulsatility index increase in capsular branches of testicular artery: indicator of impaired testicular microcirculation in varicocele? *J Clin Ultrasound.* 2007;35:191-195.
81. Pezzella A, Barbonetti A, Micillo A, et al. Ultrasonographic determination of caput epididymis diameter is strongly predictive of obstruction in the genital tract in azoospermic men with normal serum FSH. *Andrology.* 2013;1:133-138.
82. La Vignera S, Calogero AE, Condorelli RA, et al. Ultrasonographic evaluation of patients with male accessory gland infection. *Andrologia.* 2012;44(Suppl 1):26-31.
83. Sullivan R, Mieusset R. The human epididymis: its function in sperm maturation. *Hum Reprod Update.* 2016;22:574-587.
84. Elfgen V, Mietens A, Mewe M, Hau T, Middendorff R. Contractility of the epididymal duct: function, regulation and potential drug effects. *Reproduction.* 2018;156:R125-R141.
85. Singh R, Hamada AJ, Bukavina L, Agarwal A. Physical deformities relevant to male infertility. *Nat Rev Urol.* 2012;9:156-174.
86. Lotti F, Corona G, Mancini M, et al. Ultrasonographic and clinical correlates of seminal plasma interleukin-8 levels in patients attending an andrology clinic for infertility. *Int J Androl.* 2011;34(6 Pt 1):600-613.
87. Lotti F, Maggi M. Interleukin 8 and the male genital tract. *J Reprod Immunol.* 2013;100:54-65.
88. Rastrelli G, Lotti F, Reisman Y, Sforza A, Maggi M, Corona G. Metabolically healthy and unhealthy obesity in erectile dysfunction and male infertility. *Expert Rev Endocrinol Metab.* 2019;14:321-334.
89. Lotti F, Corona G, Colpi GM, et al. Elevated body mass index correlates with higher seminal plasma interleukin 8 levels and ultrasonographic abnormalities of the prostate in men attending an andrology clinic for infertility. *J Endocrinol Invest.* 2011;34(10):e336-e342.
90. Tajar A, Forti G, O'Neill TW, et al. Characteristics of secondary, primary, and compensated hypogonadism in aging men: evidence from the European Male Ageing Study. *J Clin Endocrinol Metab.* 2010;95:1810-1818.

How to cite this article: Lotti F, Frizza F, Balercia G, et al. The European Academy of Andrology (EAA) ultrasound study on healthy, fertile men: Scrotal ultrasound reference ranges and associations with clinical, seminal, and biochemical characteristics. *Andrology.* 2021;9:559-576. <https://doi.org/10.1111/andr.12951>