

Is Biochemical Screening for Pheochromocytoma in Adrenal Incidentalomas Expressing Low Unenhanced Attenuation on Computed Tomography Necessary?

T. Sane, C. Schalin-Jäntti, and M. Raade

Department of Medicine (T.S., C.S.-J.), Division of Endocrinology, and Department of Medicine, Division of Endocrinology, and Department of Radiology (M.R.), Helsinki University Central Hospital, 00029 HUS Helsinki, Finland; and University of Helsinki (C.S.-J.), 00140 Helsinki, Finland

Objective: Pheochromocytomas are characterized by a high attenuation value on unenhanced computed tomography (CT). It is not known whether pheochromocytoma could be ruled out as a cause of adrenal incidentalomas on the basis of unenhanced attenuation values only.

Design: We retrospectively evaluated the outcome of routine biochemical screening for pheochromocytoma in a series of adrenal incidentalomas in relationship to the unenhanced attenuation values on CT.

Methods: An unenhanced CT was available in 174 of 184 patients with 214 adrenal incidentalomas. All patients were screened for pheochromocytoma with 24-h urinary metanephrines and normetanephrines and for hypercortisolism (1 mg dexamethasone test and ACTH). Hypertensive patients were screened for aldosterone overproduction (aldosterone to renin ratio and 24 h urinary aldosterone). The results were compared between incidentalomas with high [≥ 10 Hounsfield units (HU)] and low (< 10 HU) unenhanced attenuation values.

Results: One hundred forty-six incidentalomas in 115 patients had an unenhanced HU less than 10. None of these patients had elevated 24-h fractionated urinary metanephrines or normetanephrines suggesting pheochromocytoma. Sixty-eight incidentalomas in 59 patients had an unenhanced HU of 10 or greater, and nine (15.2%) of these patients had surgically and histologically verified pheochromocytoma. Incidentalomas with a HU of 10 or greater were significantly larger (2.6 ± 1.5 vs. 2.3 ± 1.2 cm; $P < 0.001$), more often functional (27.9 vs. 8.9%, $P < 0.001$), and more often operated (44.1 vs. 10.2%; $P < 0.001$) than those with a Hounsfield unit less than 10.

Conclusion: The results of this study indicate that routine biochemical screening of pheochromocytoma in small homogenous adrenal incidentalomas characterized by an unenhanced Hounsfield unit value less than 10 HU may not be necessary. (*J Clin Endocrinol Metab* 97: 2077–2083, 2012)

A symptomatic adrenal masses are a common incidental finding in imaging studies done for various reasons not related to adrenal disease. The prevalence of adrenal incidentalomas increases with age, and it ranges from 1 to 8.7% (1–6). Most adrenal incidentalomas are lipid-rich cortical adenomas (1, 2, 6–8), which can be differentiated from other adrenal masses on the basis of their low unenhanced attenuation value (< 10 Hounsfield units (HU)) on computed tomography (CT) (3, 5, 9–11).

About 5% of the adrenal incidentalomas represent asymptomatic pheochromocytomas arising from neuroendocrine chromaffin cells of the adrenal medulla, but some series reported a wide variation in the prevalence of pheochromocytomas ranging from 0% to as high as 23.3% (1, 2, 7). Many recent statements on the evaluation of adrenal incidentalomas therefore recommend measurements of fractionated plasma or 24-h urinary metanephrines and normetanephrines in all patients with adrenal

TABLE 1. The most common indications for abdominal or chest CT scan in study patients

Indication	Number of patients (%)
Abdominal pain	46 (25.0)
Pulmonary infection or unclear finding on chest x-ray	29 (15.7)
Chest or loin pain or suspicion of renal colic	26 (14.0)
Abdominal infection	15 (8.1)
Follow-up of previous cancer	14 (7.6)
Fever of undetermined origin	12 (6.5)
Abdominal trauma or hemorrhage	11 (5.9)
Pulmonary embolism	7 (3.8)
Other unlisted indications altogether	24 (13.0)

incidentalomas (3–6, 12). However, pheochromocytomas are characterized by a high unenhanced attenuation value (>20 HU) on CT and only very rarely have a high lipid content (11, 13–15). Whether pheochromocytoma could be ruled out as a cause of adrenal incidentaloma on the basis of unenhanced attenuation values only is unclear. In this study we retrospectively evaluated the outcome of routine biochemical screening for pheochromocytoma in patients with adrenal incidentalomas that are characterized by a low unenhanced attenuation value (<10 HU) on CT imaging.

Materials and Methods

Materials

The study material consists of 184 patients who were referred to the outpatient Department of Endocrinology at the Helsinki University Central Hospital between January 1, 2007, and December 31, 2009, because of an adrenal mass, which had been detected incidentally on abdominal or chest CT. Only adrenal masses of 10 mm or more were included in the study. Patients diagnosed with or treated for any cancer within 5 yr were excluded from the study. The clinical indications for the CT images performed are given in Table 1. Acute abdominal pain was the most common indication, covering 25% of the cases. The clinical data and results of hormonal evaluation of the study patients were collected from the patient records by the authors (C.S.-J. and T.S.).

Imaging studies

The initial CT imaging had been performed on different scanners available at various hospitals in the Helsinki and Uusimaa Hospital District, with a slice thickness ranging from 2.5 to 5 mm. In all study subjects, at least one repeat adrenal CT imaging using a 3-mm-slice thickness was performed at the Department of Radiology at the Helsinki University Central Hospital. Unenhanced adrenal CT images were available in 174 of the study subjects (94.5%), who had altogether 214 separate adrenal masses (Fig. 1). CT imaging data were evaluated by an experienced adrenal radiologist (M.R.). The maximal diameter of the adrenal mass was determined with a distance cursor in the axial plane of the CT scan. The density of the adrenal mass expressed

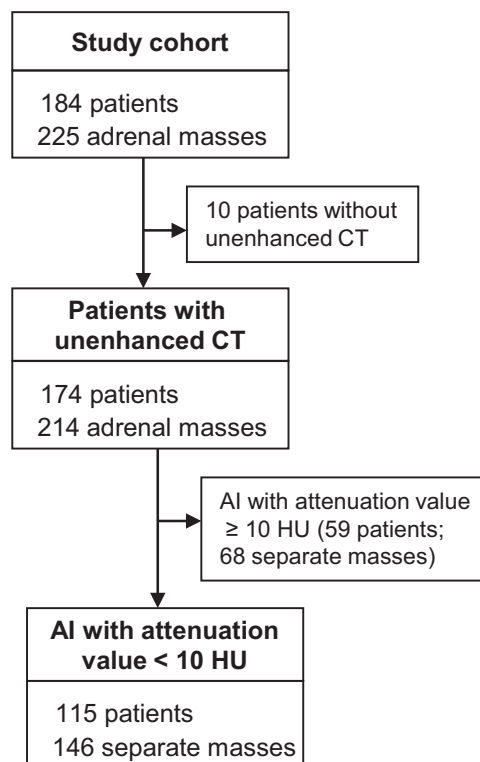


FIG. 1. The original study cohort with adrenal incidentaloma (AI) and number of patients from whom unenhanced attenuation values on CT were available and who were included in the final analyses.

as Hounsfield unit values was measured from unenhanced CT scans by using a circular region-of-interest cursor placed over the center of the adrenal incidentaloma, avoiding edges, calcifications, and cystic or necrotic lesions of the mass. One to three region-of-interest measurements were obtained for each adrenal mass, and the mean value of these measurements were used in the final analysis.

Biochemical analysis

All laboratory measurements were performed at HUSLAB, the laboratory of the Helsinki University Central Hospital, using standard assays. For biochemical evaluation of the pheochromocytoma, 24-h urine collections were performed in all study subjects and fractionated urinary metanephrine (reference value <1.7 μmol) and normetanephrine (reference value <4.0 μmol) were measured by HPLC. For the evaluation of autonomous cortisol production, an overnight dexamethasone suppression test was performed with a dose of 1 mg, taken at 2300 h, and blood samples for the determination of serum cortisol were drawn at 0800 h the following morning. Serum cortisol was measured with liquid chromatography-tandem mass spectrometry. Plasma ACTH was determined with an immunochemiluminometric assay. The cutoff criteria for autonomous cortisol production were impaired suppression of serum cortisol greater than 100 nmol/liter after an overnight 1-mg dexamethasone suppression test and a low plasma ACTH concentration of less than 10 ng/liter (reference value <46 ng/liter). The plasma renin activity and serum aldosterone were measured with RIA in hypertensive patients. The criteria for aldosterone overproduction were an increased aldosterone to renin ratio (>800) and an increased diurnal aldosterone excretion (>40 nmol).

Ethics

The study was approved by the Ethics Committee of the Helsinki University Central Hospital and the Board of the Department of Internal Medicine. All results are given as means \pm SD. The statistical difference between the subgroups was analyzed with the Student's *t* test when appropriate and with χ^2 and a Kruskal Wallis test for categorical data. Correlation analysis was based on a Pearson's correlation test. Statistical analyses were performed with the SPSS version 19.0 for Windows (SPSS Inc., Chicago, IL). A value of $P < 0.05$ was considered statistically significant.

Results

Clinical characteristics and localization of adrenal incidentalomas

The demographic data of the 184 study patients are shown in Table 2. The age range was 19–88 yr, and the majority was females (59.2%). The total number of separately detected adrenal masses on CT was 225. Of all study patients, 151 (82%) had either one ($n = 145$) or two ($n = 6$) separate unilateral adrenal incidentalomas, and 33 patients (18%) had either two ($n = 31$) or even three ($n = 2$) separate incidentalomas bilaterally. Of all 225 adrenal masses, 136 (60.4%) were located in the left adrenal gland and 89 (39.6%) in the right adrenal gland. The mean size was 2.3 ± 1.2 cm, but 108 (48%) of the incidentalomas were 2 cm or less in size. Only 18 of the adrenal incidentalomas (8%) were larger than 4 cm.

Adrenal incidentalomas with an unenhanced attenuation value less than 10 HU

A noncontrast CT was available in 174 patients having 214 separate adrenal masses (Fig. 1). Of all incidentalomas,

146 masses in 115 patients (68.2%) had an unenhanced attenuation value less than 10 HU (lipid rich incidentalomas). The size of the lipid-rich incidentalomas ranged from 1.0 to 6.9 cm and half of them were of 2 cm or less in size (Table 2). The proportion of large tumors (diameter > 4 cm) among lipid-rich incidentalomas was small, 3.4%. Functional activity was verified in 11 of the lipid-rich tumors (nine with cortisol and two with aldosterone overproduction). These were laparoscopically removed and histologically verified as cortical adenomas. Moreover, two other incidentalomas with low attenuation on CT were removed due to their large size (> 4 cm). One of them was a nonfunctional large adenoma and the other one proved to be a remnant of an old adrenal hematoma.

The results of the urinary metanephrine and normetanephrine measurements in patients with an incidentaloma characterized by a low unenhanced attenuation value (< 10 HU) are shown in Fig. 2. Slightly elevated 24-h urinary metanephrine or normetanephrine secretion was observed in only one patient each. In both patients, control measurements of 24-h urinary metanephrine and normetanephrine were normal. None of the 115 patients with low unenhanced attenuation had a pheochromocytoma.

Adrenal incidentaloma with an unenhanced attenuation value of 10 HU or greater

Of the 174 patients from whom unenhanced CT imaging was available, 68 incidentalomas were characterized by a Hounsfield unit value of 10 or greater (Table 2). The age and sex distribution did not differ from the subjects with lipid-rich incidentalomas (HU < 10 ; $n = 115$),

TABLE 2. Clinical data of study patients with adrenal incidentalomas

	All patients with incidentaloma	Patients with unenhanced attenuation value < 10 HU	Patients with unenhanced attenuation value ≥ 10 HU
Number of patients	184	115	59
Age (yr)	60.7 ± 10.8	61.2 ± 10.2	59.2 ± 10.8
Sex (males/females)	75/109	49/66	22/37
Body mass index (kg/m^2)	28.2 ± 6.2	28.4 ± 6.2	27.7 ± 5.9
History of hypertension (%)	90 (40%)	56 (38.2%)	26 (38.4%)
Number of tumors	225	146	68
Diameter, mean (cm)	2.3 ± 1.2	2.1 ± 1.0	2.6 ± 1.5^a
≤ 2 (%)	108 (48.0%)	74 (52.1%)	27 (39.7%)
2–4 (%)	101 (44.9%)	67 (44.5%)	31 (45.6%)
> 4 (%)	16 (7.1%)	5 (3.4%)	10 (14.7%) ^a
Side			
Left (%)	136 (60.4%)	91 (62.3%)	38 (55.9%)
Right (%)	89 (39.6%)	55 (37.7%)	30 (44.1%)
Functional (percent of tumors)	41 (18.2%)	13 (8.9%)	19 (27.9%) ^b
Operated (percent of tumors)	52 (23.1%) ^c	15 (10.2%)	30 (44.1%) ^{b,c}

^a $P < 0.01$ for the difference between the subgroups.

^b $P < 0.001$ for the difference between the subgroups.

^c Bilateral tumors were removed in one patient.

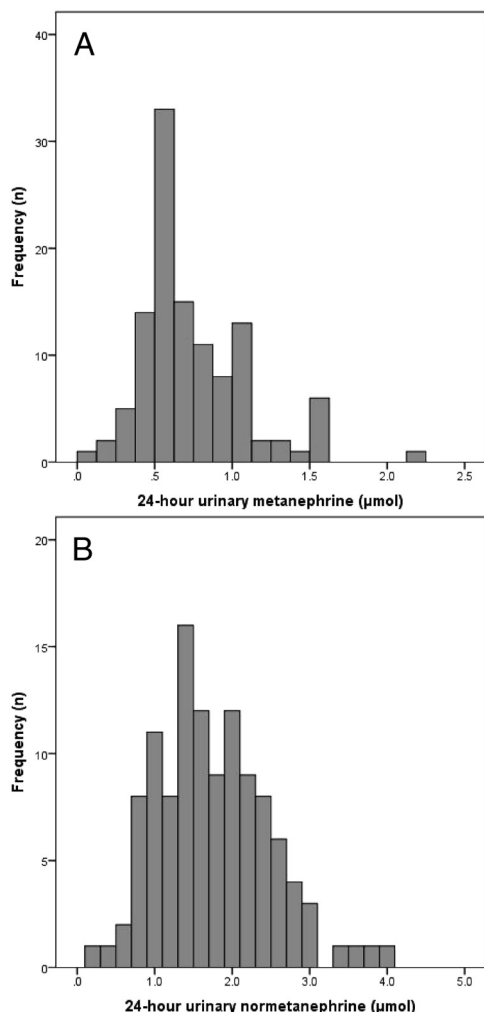


FIG. 2. Distribution of 24-hr fractionated urinary metanephrine (A) and normetanephrine (B) in patients with adrenal incidentaloma and an unenhanced HU less than 10.

but the mean diameter of the incidentaloma was significantly longer ($P < 0.01$), and there was a higher proportion of incidentalomas larger than 4 cm ($P < 0.01$) (Table 2). In addition, incidentalomas with a high unenhanced Hounsfield unit value were significantly more often func-

tional and operated compared with those with a low attenuation value ($P < 0.001$; Table 2).

Pheochromocytoma was biochemically verified and operated in nine patients with an unenhanced HU greater than 20 and in one patient from whom only enhanced CT imaging was available (Table 3). The pheochromocytoma was located in the right adrenal gland in seven (77.7%) and in the left adrenal in one patient. One male patient had bilateral pheochromocytoma due to previously undiagnosed multiple endocrine neoplasia-2A syndrome. Anti-hypertensive agents were as common in patients with pheochromocytoma as in patients with lipid-rich incidentalomas. Eighteen other patients were characterized by a high unenhanced Hounsfield unit of 10 or greater and operated due to either large size (>4 cm) or atypical radiological appearance or increase in size during follow-up. Ten of the patients had lipid-poor adenomas, two adrenocortical carcinomas, two hematomas, and one each a schwannoma, ganglioneuroma, or bilateral B cell lymphoma. One patient had an adrenal metastasis of renal cancer. The primary tumor had been operated 6 yr earlier without any signs of recurrence on follow-up.

Change in size of nonoperated adrenal incidentalomas during follow-up

One hundred thirty-one incidentalomas with an unenhanced Hounsfield unit value of less than 10 were not operated and followed up by a repeat CT performed on average 15.8 months (median 13, range 0–60 months) later. In some of these patients, the incidentaloma could retrospectively be identified on previously done CT. The mean diameter of the lipid-rich incidentalomas did not increase (change 0.0 ± 0.1 cm) during follow-up and none grew more than 0.5 cm in size. Forty incidentalomas with an unenhanced Hounsfield unit value of 10 or greater were not operated and followed up with a CT performed on average 22.6 months (range 3–52 months) later. No in-

TABLE 3. Clinical data of patients with surgically proven pheochromocytoma

Sex	Age (yr)	Previous treatment of hypertension	Blood pressure (mm Hg) ^a	Size (cm)	Side	Attenuation value (HU)	24-h urine metanephrines (μmol) (reference <1.7 μmol)	24-h urine normetanephrines (μmol) (reference <4 μmol)
F	88	Yes	152/63	3.2	Right	36.5	6.4	4.4
M	40	No	134/77	5.1	Right	51.8	9.0	29.0
M	62	Yes	150/98	6.7	Right	40.9	40.0	102
F	55	No	130/80	3.4	Right	41.0	9.5	2.8
M	77	Yes	147/102	5.4	Right		0.2	15.7
F	63	No	142/88	2.2	Left	38.7	3.8	2.4
M	54	No	140/86	4.8	Right	25.2	32.3	13.7
				2.4	Left	26.3		
M	49	No	163/108	4.5	Right	66.6	0.4	15.5
F	59	No	140/90	2.6	Right	34	3.1	3.4

^a Measured at the Outpatient Clinic at the Endocrine Department, Helsinki University Central Hospital.

crease in mean size (0.0 ± 0.1 cm) was observed. Only two of these incidentalomas increased more than 0.5 cm in size.

Discussion

We here report, for the first time, the outcome of routine biochemical screening for pheochromocytoma in adrenal incidentalomas with a low unenhanced attenuation value on CT. Adrenal incidentalomas with a low unenhanced attenuation value on CT are usually nonfunctioning or functioning benign cortical adenomas. In our study cohort, about half of the incidentalomas with a low unenhanced Hounsfield unit were less than 2 cm in size. We demonstrate that none of these 115 patients, having altogether 145 separate lipid-rich incidentalomas (unenhanced HU <10), had constantly elevated 24-h urinary metanephrines or normetanephrines as a biochemical marker of pheochromocytoma. In the present study, 10 pheochromocytomas were surgically and histologically confirmed, but none of the nine patients evaluated with unenhanced CT was characterized by a Hounsfield unit value less than 10.

Our study cohort included consecutive patients referred to a tertiary care setting because of an adrenal incidentaloma during a time period of 3 yr. The indications for CT scanning were either abdominal symptoms or suspicion of chest disease; our study cohort can therefore be considered representative without selection bias. In line with this, the prevalence of cortical carcinomas was low (1.1%) and close to that of 1.9% given in a very recent review by Zeiger *et al.* (5). Furthermore, mean age and sex distribution of our study patients were very close to that of a large Italian survey on 1004 adrenal incidentalomas (7). Female predominance also has been reported in other series (2). Interestingly, in our study cohort, the incidentaloma was more often found in the left and not the right adrenal; this finding differs from what has been reported in other series (2). The prevalence of pheochromocytomas in our study was 4.8%, which also is in close line with that reported in many recent reviews and meta-analyses (2, 3, 10).

Of all patients with pheochromocytomas, approximately 10% are discovered incidentally. On CT, pheochromocytomas usually appear round and smooth but may include cystic, necrotic, or even hemorrhagic areas. On contrast-enhanced CT, they enhance avidly but enhancement is often heterogeneous (3, 16). Regardless of whether the pheochromocytoma was symptomatic or discovered incidentally, the unenhanced attenuation value of pheochromocytomas on CT is usually greater than 30 HU as reported in many series (8, 9, 11, 17, 18). Of altogether

146 symptomatic or incidentally discovered adrenal pheochromocytomas reported in the literature, all were characterized by an unenhanced attenuation value of 10 HU or greater (9, 11, 17–21). This was the case also in a recently reported patient with a small slowly growing pheochromocytoma (22). During the present study period (years 2007–2009), 19 symptomatic patients were diagnosed with and operated for pheochromocytoma in our hospital. A noncontrast CT was performed before the operation in 10 of these patients. In line with the findings of the incidentally discovered pheochromocytomas, they were all characterized by an unenhanced HU greater than 10 and a heterogeneous appearance on CT.

Lipid degeneration, mimicking lipid-rich cortical adenomas, has only very rarely been discovered histologically in pheochromocytoma (13, 23). The first two reports of lipid-rich pheochromocytomas were in young symptomatic patients with hereditary pheochromocytomas (12, 23). However, data on CT attenuation were not reported for these two cases. Blake *et al.* reported that in two of nine patients with symptomatic adrenal pheochromocytoma, unenhanced attenuation was less than 10 HU (14). However, these tumors were very small in size, less than 1.5 cm and one of the reported patients had in fact adrenal medullary hyperplasia and not pheochromocytoma (11). Karstaedt *et al.* (24) reported four patients with symptomatic pheochromocytomas and a low attenuation value on a CT scan performed with 1-cm slices. Two of them were heterogeneous and had a well-defined rim of higher density. However, the pathology specimens demonstrated also necrotic tissue, which accounted for the low density of these pheochromocytomas. To date, it is well recognized that necrotic tumor areas should be avoided when evaluating the density.

To the best of our knowledge, there are no reports of incidentally discovered pheochromocytomas characterized by a low unenhanced attenuation value in the literature. Most of the large clinical case series on adrenal incidentalomas do not include data on CT attenuation. In the present study, none of the incidentally found pheochromocytomas were characterized by low unenhanced attenuation on CT. On the other hand, we cannot completely exclude the possibility of pheochromocytoma among lipid-rich adrenal tumors. However, this seems unlikely because we did follow the patients with lipid rich adrenal tumors for an average of 15 months, and none of these patients showed clinical symptoms of pheochromocytoma or had an increase in size of their adrenal mass during this time period.

There is consensus that fractionated urinary metanephrines instead of total metanephrines should be measured because this method is more sensitive (5, 6, 25). However,

the issue of whether plasma-free or fractionated urinary metanephrines offer the best initial screening test remains largely unsolved (24). Measurements of plasma-free metanephrines are a more recent method, with a sensitivity of 99 vs. 97% for fractionated urinary metanephrines, with a higher specificity (26, 27). In the present study, we used 24-h urine metanephrine and normetanephrine measurements as suggested in a very recent review and position statement for the evaluation of adrenal incidentalomas (5, 6). The patients included in the present study were screened for pheochromocytoma during the years 2007–2009, when measurements of plasma free metanephrines were not yet available at the Helsinki University Central Hospital Laboratory. Although the question remains theoretical, there is a slight possibility that determination of plasma free metanephrines would have performed differently. It has been suggested that plasma metanephrines should be used in populations at high risk of pheochromocytoma, such as in relatives of patients with hereditary pheochromocytoma (28). We are not aware of any studies in patients with adrenal incidentalomas only where these two methods would have been directly compared.

In conclusion, this is the first study evaluating the benefit of routine biochemical screening of pheochromocytomas in patients with adrenal incidentalomas characterized by a low unenhanced Hounsfield unit value on CT. According to our data, the routine measurements of fractionated urinary metanephrines in an asymptomatic patient with incidentally discovered small adrenal masses may not be necessary, provided that the unenhanced attenuation value on CT is less than 10 HU and that the appearance of the adrenal mass is homogenous. However, if the incidentaloma is first discovered on contrast-enhanced CT imaging or if it has heterogeneous appearance on noncontrast CT, measurements of urinary or plasma fractionated metanephrines is mandatory to rapidly exclude the possibility of pheochromocytoma. If biochemical screening indicates pheochromocytoma, there is no need for an unenhanced CT imaging in addition to the enhanced scan, and unnecessary exposure to ionization radiation can thus be avoided. It is important to confirm the results of the present study in larger case series in the future.

Acknowledgments

Address all correspondence and requests for reprints to: Timo Sane, M.D., Ph.D., Department of Medicine, Division of Endocrinology, Helsinki University Central Hospital, P.O. Box 340, 00029 HUS Finland. E-mail: timo.sane@hus.fi.

Disclosure Summary: The authors have nothing to disclose.

References

- Bülöw B, Åhrén B Swedish Research Council Study Group of Endocrine Abdominal Tumors 2002 Adrenal incidentaloma—experience of a standardized diagnostic program in the Swedish prospective study. *J Intern Med* 252:239–246
- Barzon L, Sonino N, Fallo F, Palu G, Boscaro M 2003 Prevalence and natural history of adrenal incidentaloma. *Eur J Endocrinol* 149:273–285
- Young Jr JE 2007 The incidentally discovered adrenal mass. *N Engl J Med* 356:601–610
- Terzolo M, Bovio S, Pia A, Reimondo G, Angeli A 2009 Management of adrenal incidentaloma. *Best Pract Res Clin Endocrinol Metab* 23:233–243
- Zeiger MA, Siegelman SS, Hamrahian AH 2011 Medical and surgical evaluation and treatment of adrenal incidentaloma. *J Clin Endocrinol Metab* 96:2004–2015
- Terzolo M, Stigliano A, Chodini I, Loli P, Furlano L, Arnaldi G, Reimondo G, Pia A, Toscano V, Zini M, Borretta G, Papini E, Garofalo P, Allolio B, Dupas B, Mantero F, Tabarini A; Italian Association of Endocrinologists 2011 AME position statement on adrenal incidentaloma. *Eur J Endocrinol* 164:851–870
- Mantero F, Terzolo M, Arnaldi G, Osella G, Masini AM, Ali A, Giovanetti M, Opocher G, Angeli A 2000 A survey on adrenal incidentaloma in Italy. *J Clin Endocrinol Metab* 85:637–644
- Song JH, Chaudry FJ, Mayo-Smith WW 2008 The adrenal incidental mass on CT: prevalence of adrenal diseases in 1049 consecutive adrenal masses in patients with no known malignancy. *AJR Am J Roentgenol* 190:1163–1168
- Hamrahian AH, Ioachimescu AG, Remer EM, Motta-Ramirez G, Bogabathina H, Levin HS, Reddy S, Gill IS, Siperstein A, Bravo EL 2005 Clinical utility of noncontrast computed tomography attenuation value (Hounsfield Units) to differentiate adrenal adenomas/hyperplasia from nonadenomas: Cleveland Clinic experience. *J Clin Endocrinol Metab* 90:871–877
- Boland GW, Blake MA, Hahn PF, Mayo-Smith WW 2008 Incidental adrenal lesions: principles, techniques, and algorithms for imaging characterization. *Radiology* 249:756–775
- Szolar DH, Korobkin M, Reittner P, Berghold A, Bauernhofer T, Trummer H, Schoellnast H, Preidler KW, Samonigg HH 2005 Adrenocortical carcinomas and adrenal pheochromocytomas: mass and enhancement loss evaluation at delayed contrast-enhanced CT. *Radiology* 234:479–485
- Androulakis IL, Kaltsas G, Piaditis G, Grossman AB 2011 The clinical significance of adrenal incidentalomas. *Eur J Clin Invest* 41:552–560
- Ramsay JA, Asa SL, van Nostrand AW, Hassaram ST, de Harven EP 1987 Lipid degeneration in pheochromocytoma mimicking adrenal cortical tumors. *Am J Surg Pathol* 11:480–486
- Blake MA, Krishnamoorthy SK, Boland GW, Sweeney AT, Pitman MB, Harisinghani M, Mueller PR, Hahn PF 2003 Low-density pheochromocytoma on CT: a mimicker of adrenal adenoma. *AJR Am J Roentgenol* 181:1663–1668
- Boland GW, Lee MJ, Gazelle GS, Halpern EF, McNicholas MM, Mueller PR 1998 Characterization of adrenal masses using unenhanced CT: analysis of the CT literature. *AJR Am J Roentgenol* 171:201–204
- Bhatia KSS, Ismail MM, Sahdev A, Rockall AG, Hogarth K, Canizales A, Avril N, Monson JP, Grossman AB, Reznick RH 2008 123I-metaiodobenzylguanidine (MIBG) scintigraphy for the detection of adrenal and extra-adrenal pheochromocytoma: CT and MRI correlation. *Clin Endocrinol (Oxf)* 69:181–188
- Motta-Ramirez GA, Remer EM, Herts BR, Gill IS, Hamrahian AH 2005 Comparison of CT findings in symptomatic and incidentally discovered pheochromocytomas. *AJR Am J Roentgenol* 185:684–688
- Korobkin M, Brodeur FJ, Francis IR, Quint LE, Dunnick NR, Londy

- F 1998 CT time-attenuation washout curves of adrenal adenomas and nonadenomas. *AJR Am J Roentgenol* 170:747–752
19. Caoili EM, Korobkin M, Francis IR, Cohan RH, Platt JF, Dunnick NR, Raghupathi KI 2002 Adrenal masses: characterization with combined unenhanced and delayed enhanced CT. *Radiology* 222:629–633
 20. Peña CS, Boland GW, Hahn PF, Lee MJ, Mueller PR 2000 Characterization of indeterminate (lipid-poor) adrenal masses: use of washout characteristics at contrast-enhanced CT. *Radiology* 217:798–802
 21. Park BK, Kim CK, Kwon GY, Kim JH 2007 Re-evaluation of pheochromocytomas on delayed-contrast enhanced CT: washout enhancement and other imaging features. *Eur Radiol* 17:2804–2809
 22. Sugawara T, Hashimoto T, Owada M, Kawamura M 2011 CT features of early pheochromocytoma. *Intern Med* 50:787
 23. Unger PD, Cohen JM, Thung SN, Gordon R, Pertsemlidis D, Dikman SH 1990 Lipid degeneration in a pheochromocytoma in a pheochromocytoma histologically mimicking adrenal cortical tumor. *Arch Pathol Lab Med* 114:892–894
 24. Karstaedt N, Sagel SS, Stanley RJ, Melson GL, Levitt RG 1978 Computed tomography of the adrenal gland. *Radiology* 129:723–730
 25. Eisenhofer G, Tischler AS, de Krijger RR 2012 Diagnostic tests and biomarkers for pheochromocytoma and extra-adrenal paraganglioma: from routine laboratory methods to disease stratification. *Endocr Pathol* 23:4–14
 26. Lenders JW, Pacak K, McClellan MW, Linehan WM, Mannelli M, Friberg P, Keiser HR, Goldstein DS, Eisenhofer G 2002 Biochemical diagnosis of pheochromocytoma: which test is best? *JAMA* 287:1427–1434
 27. Lenders JW, Eisenhofer G, Mannelli M, Pacak K 2005 Pheochromocytoma. *Lancet* 366:665–675
 28. Sawka AM, Jaeschke R, Singh RJ, Young Jr WF 2003 A comparison of biochemical tests for pheochromocytoma: measurement of fractionated plasma metanephrines compared with the combination of 24-hour urinary metanephrines and catecholamines. *J Clin Endocrinol Metab* 88:553–558



Visit the online store to learn more about The Endocrine Society's
new and recently released products and resources.

www.endo-society.org/store